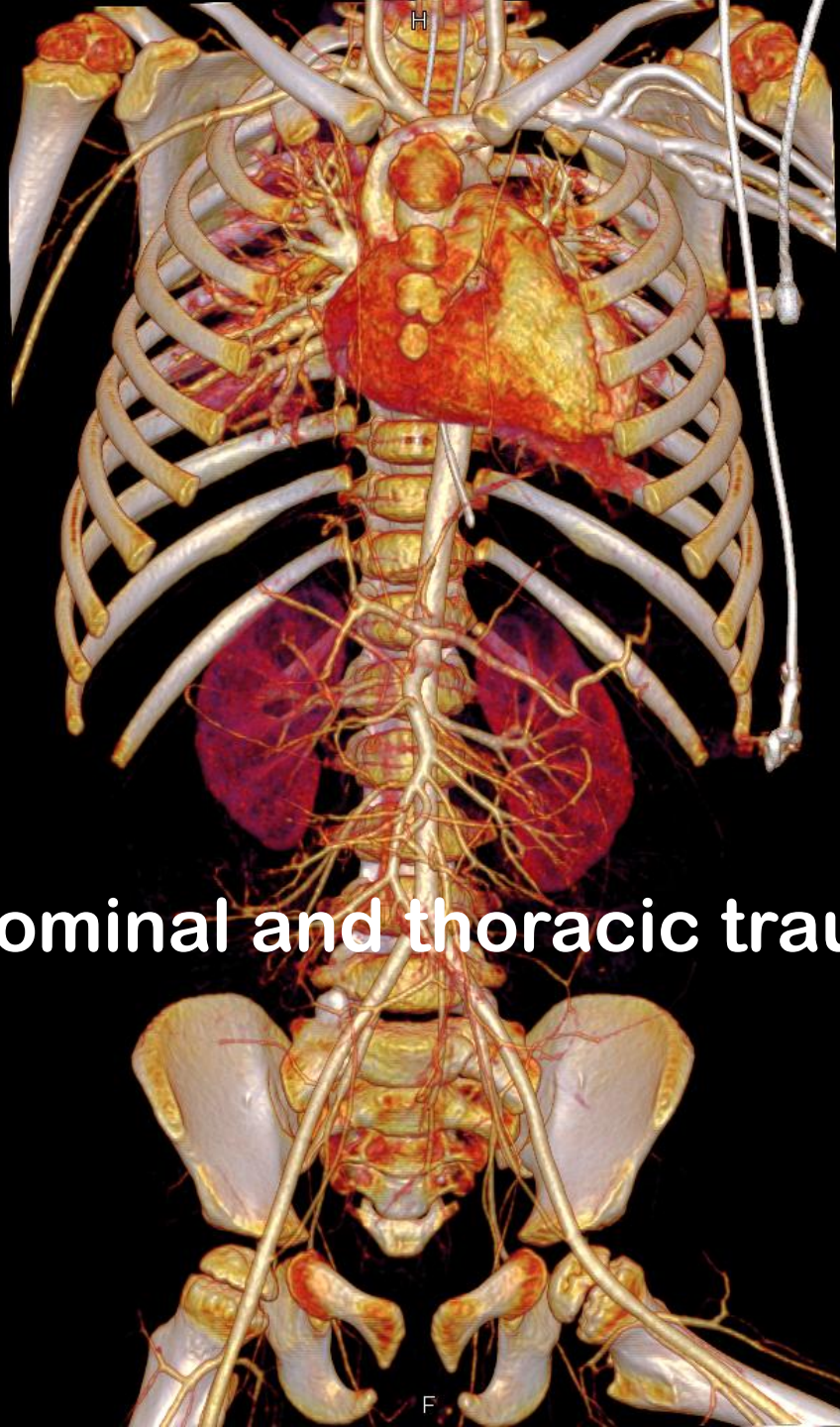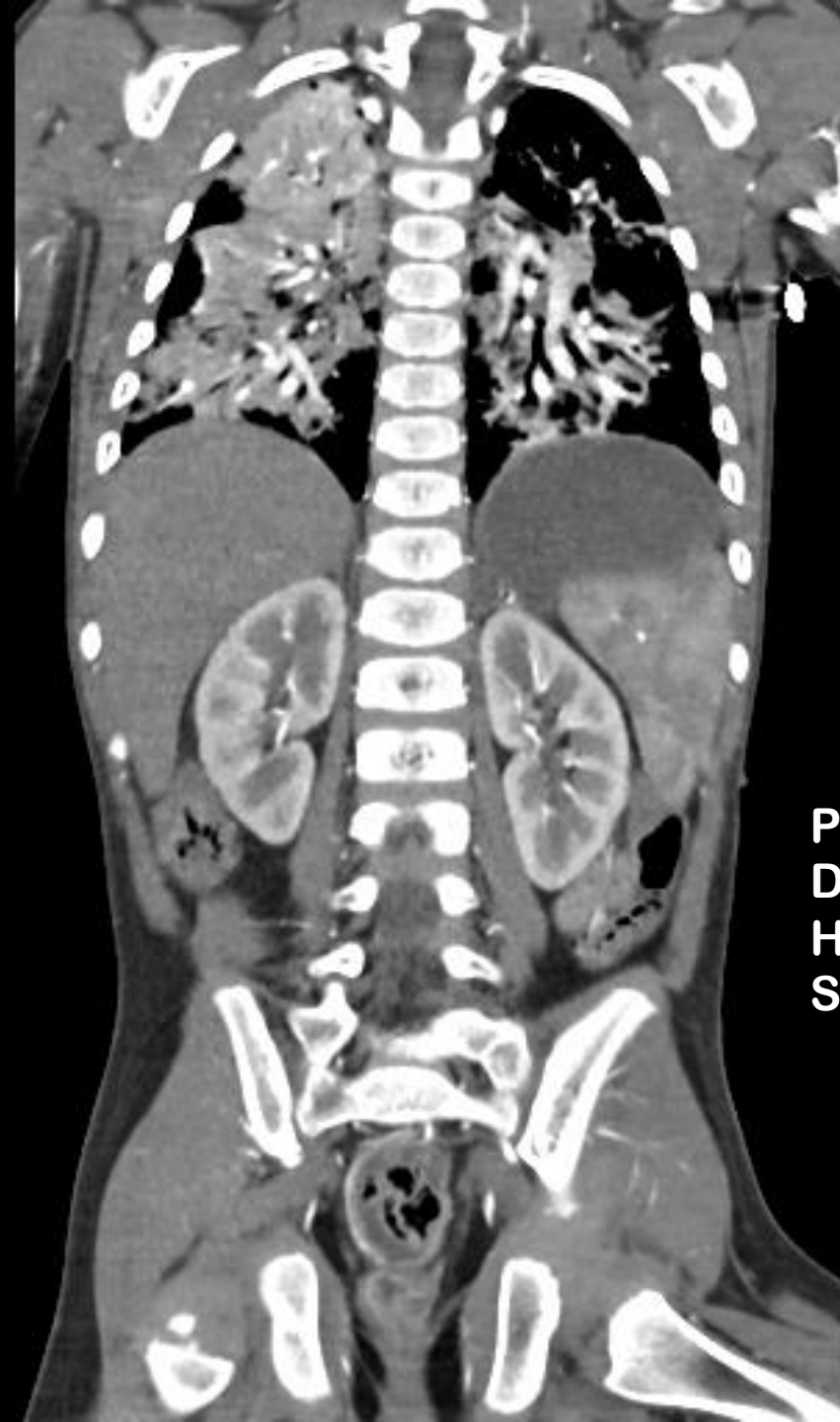


Abdominal and thoracic trauma



PD Dr. med.
Dominik
Heim,
Switzerland

We're talking mostly about:

- chest

- spleen

- kidney

- small bowel and colon

- very few reports about liver injury

liver:

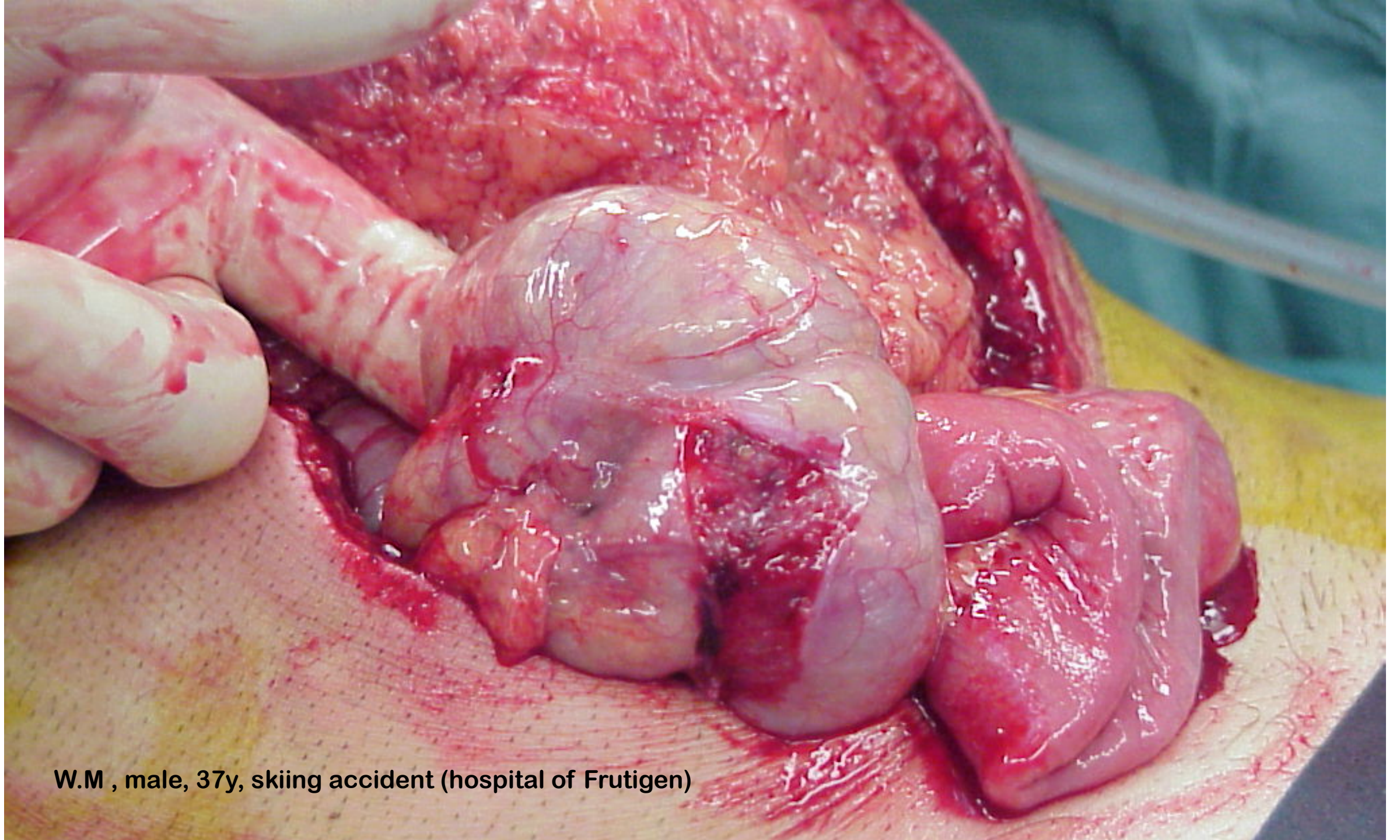
„...snowboarders commonly had injuries to the abdomen and its organs (snowboard 22% vs ski 11%). A considerable amount of snowboarders had injuries to the spleen (11%), liver (4%) and kidney (2%)



abdominal trauma at Trauma Center Chur 2007-2015:

28 intestinal perforations

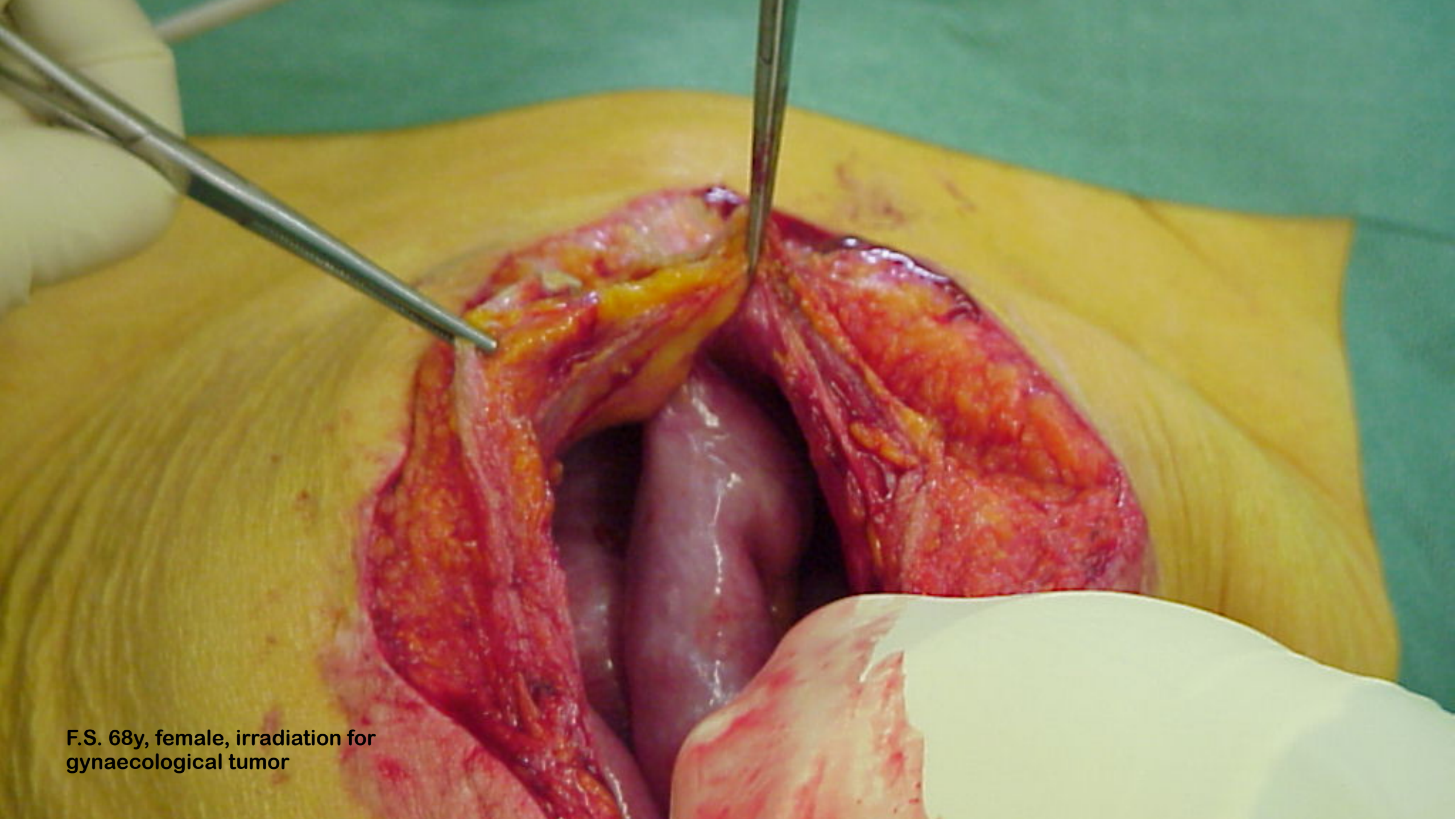
**26 blunt trauma, 2 direct
perforations**



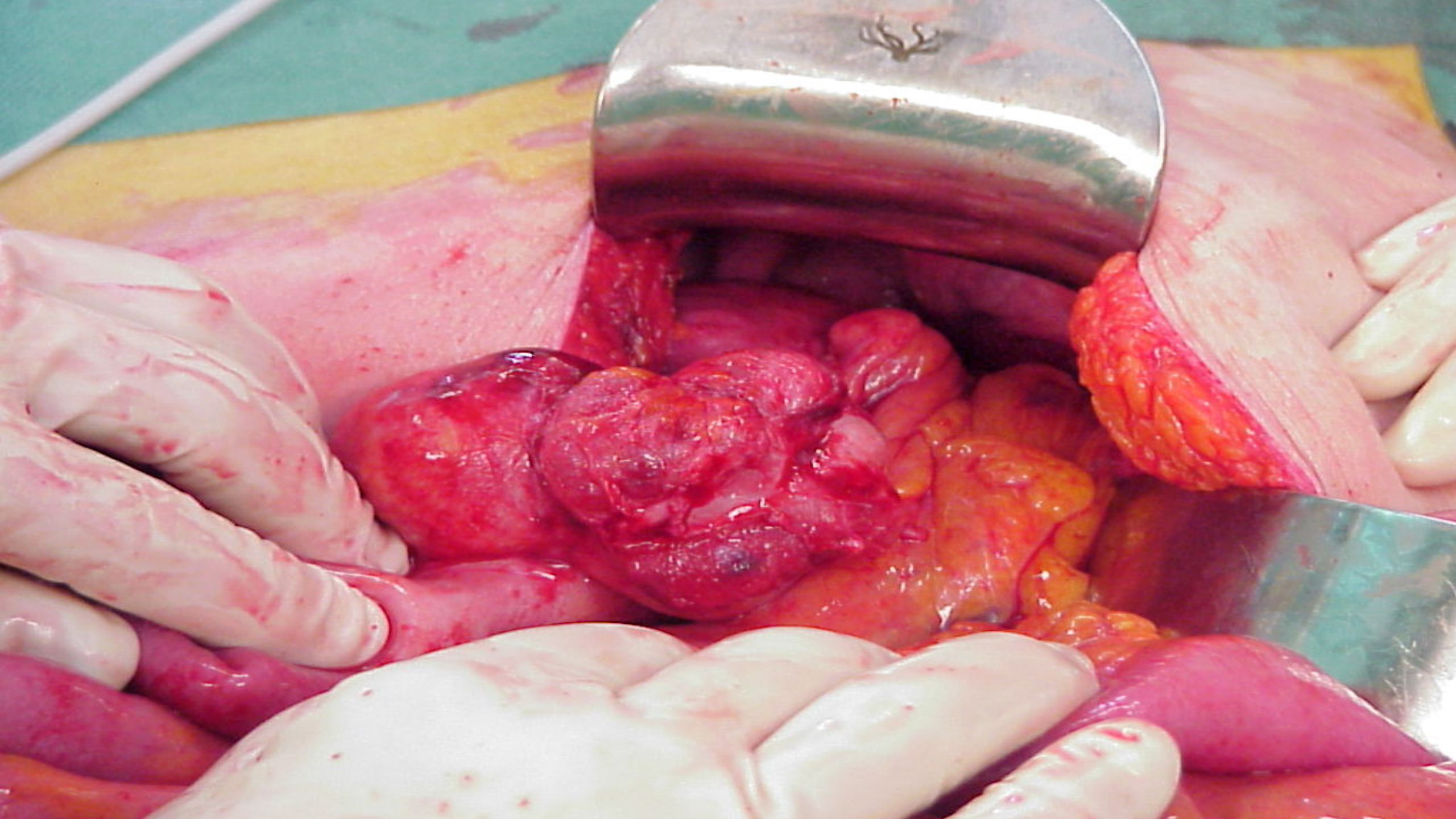
W.M , male, 37y, skiing accident (hospital of Frutigen)

**often in abdomens
with previous
surgery**

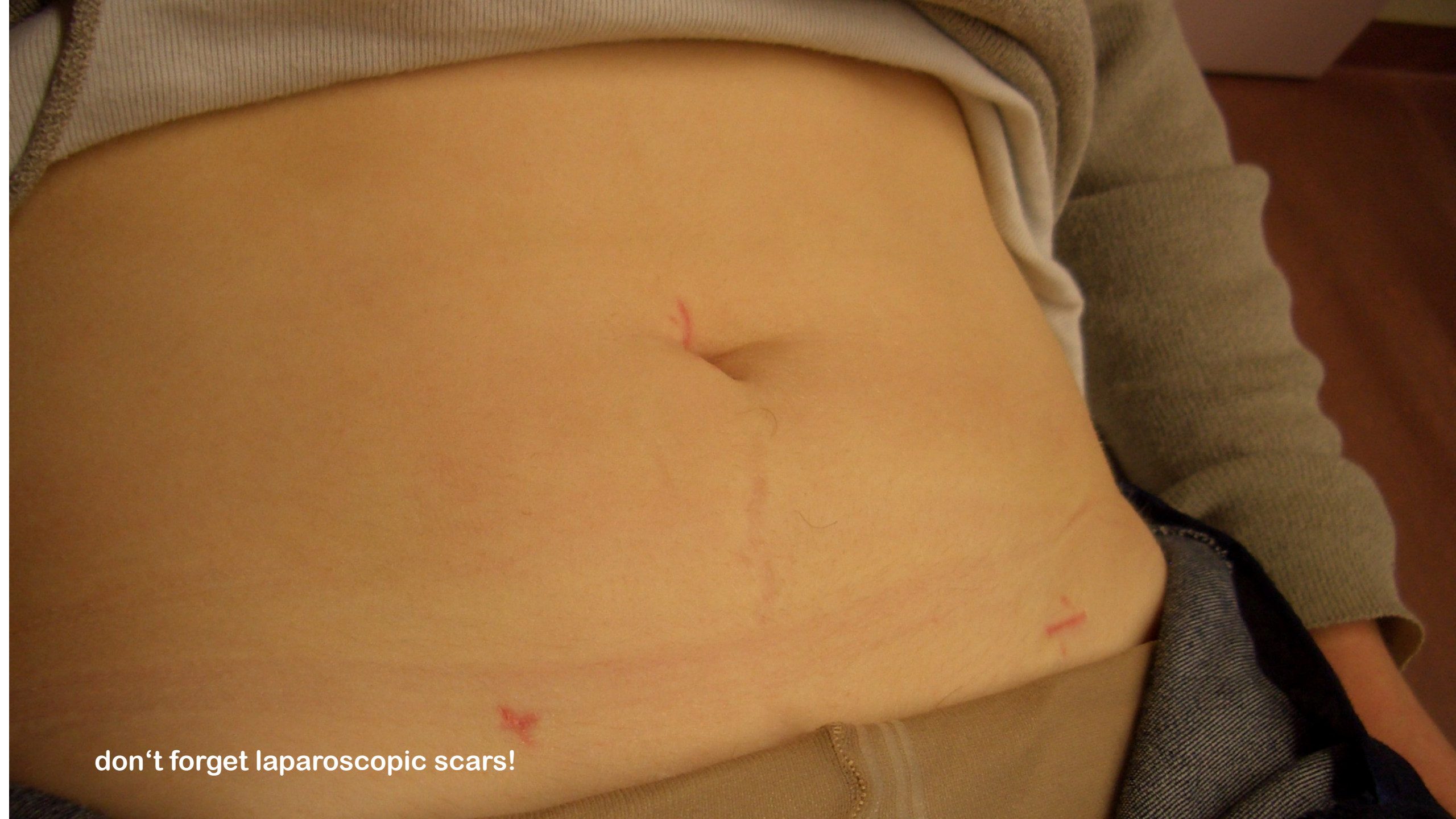personal observation (dh)



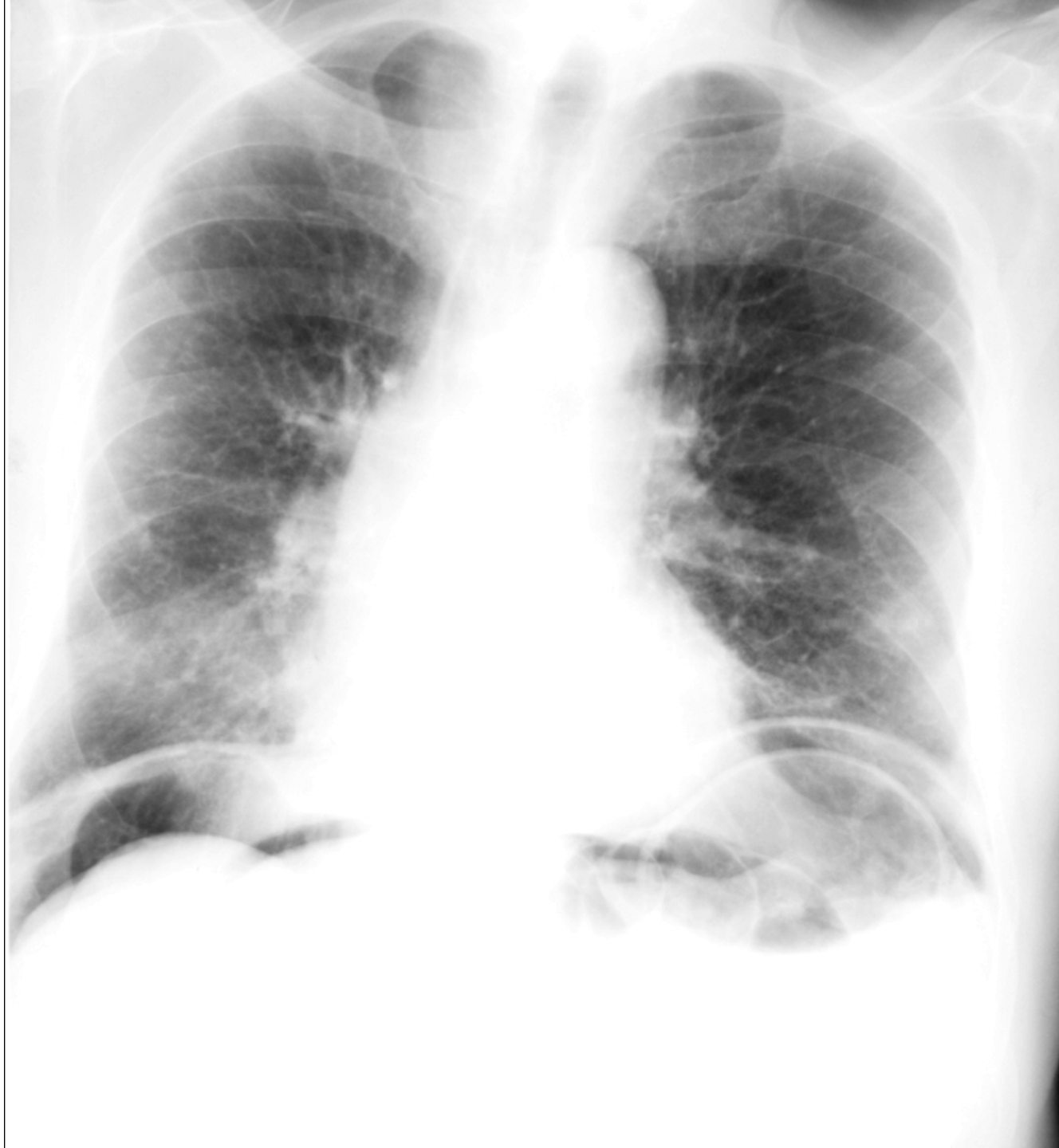F.S. 68y, female, irradiation for gynaecological tumor



**look out for scars
and ask for previous
treatments**



don't forget laparoscopic scars!

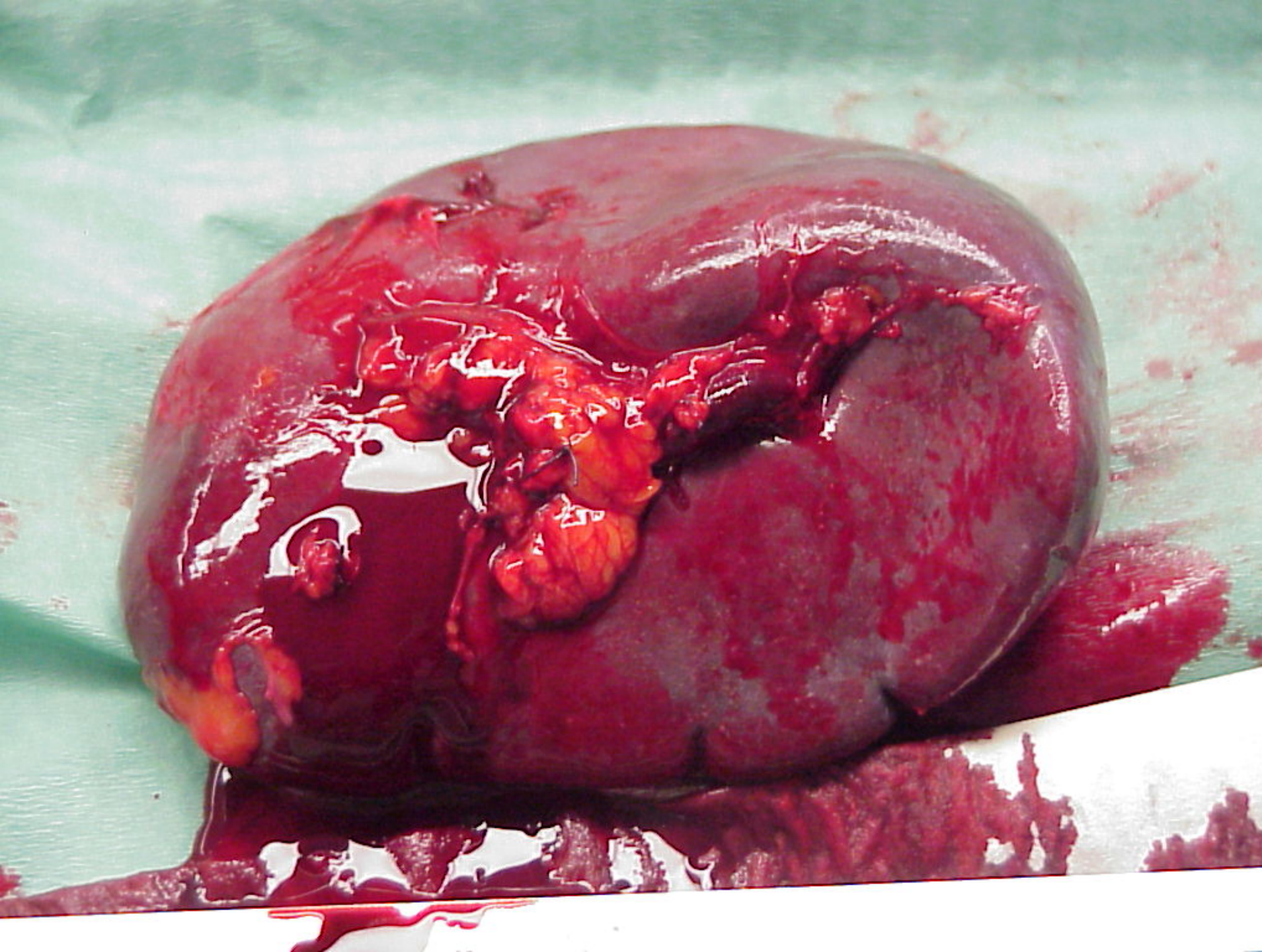


this is ...

this is ...



... too much air!



**solid
organs
or ...
„the
boarder
belly“**

Geddes R, Irish K. „...
splenic injuries resulting
from ski and snowboard
injuries. Emerg Med
Australasia 2005; 17:
157-62

Splenic injuries: snowboarder vs skier (2003/ Canada)

	snowboarder	skier
age	20.8	29
splenectomy	12(27%)	11 (50%)
multiple injury	2 (4.7%)	10 (45%)
mechanisms of injury		
- fall	70%	36%
- jump	26%	14%
- collision	5%	50%

spleen:

12 years experience medical Center of Vermont

**10/ 18 concomitant renal
injuries**

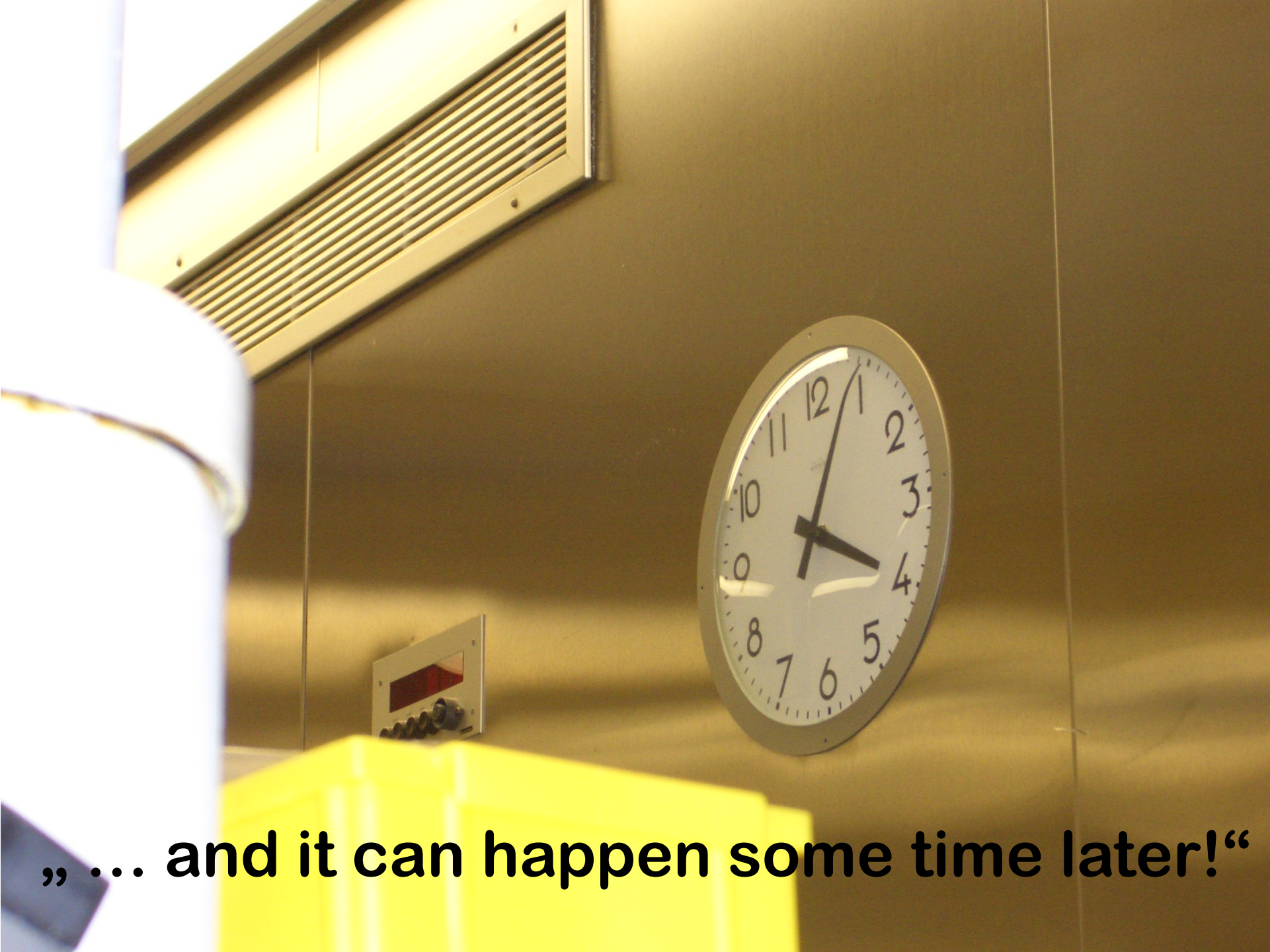Sartorelli KH et al. Injury 1995;

mechanism for splenic injury:

- snowboarder: falling with their left elbow flexed and adducted

- ski: collision

**„rescuers need to
retain a high index of
suspicion for any
snowboarder who
complains of abdominal
pain after a fall or jump“**



„ ... and it can happen some time later!“

B.U, 57y, male, skier

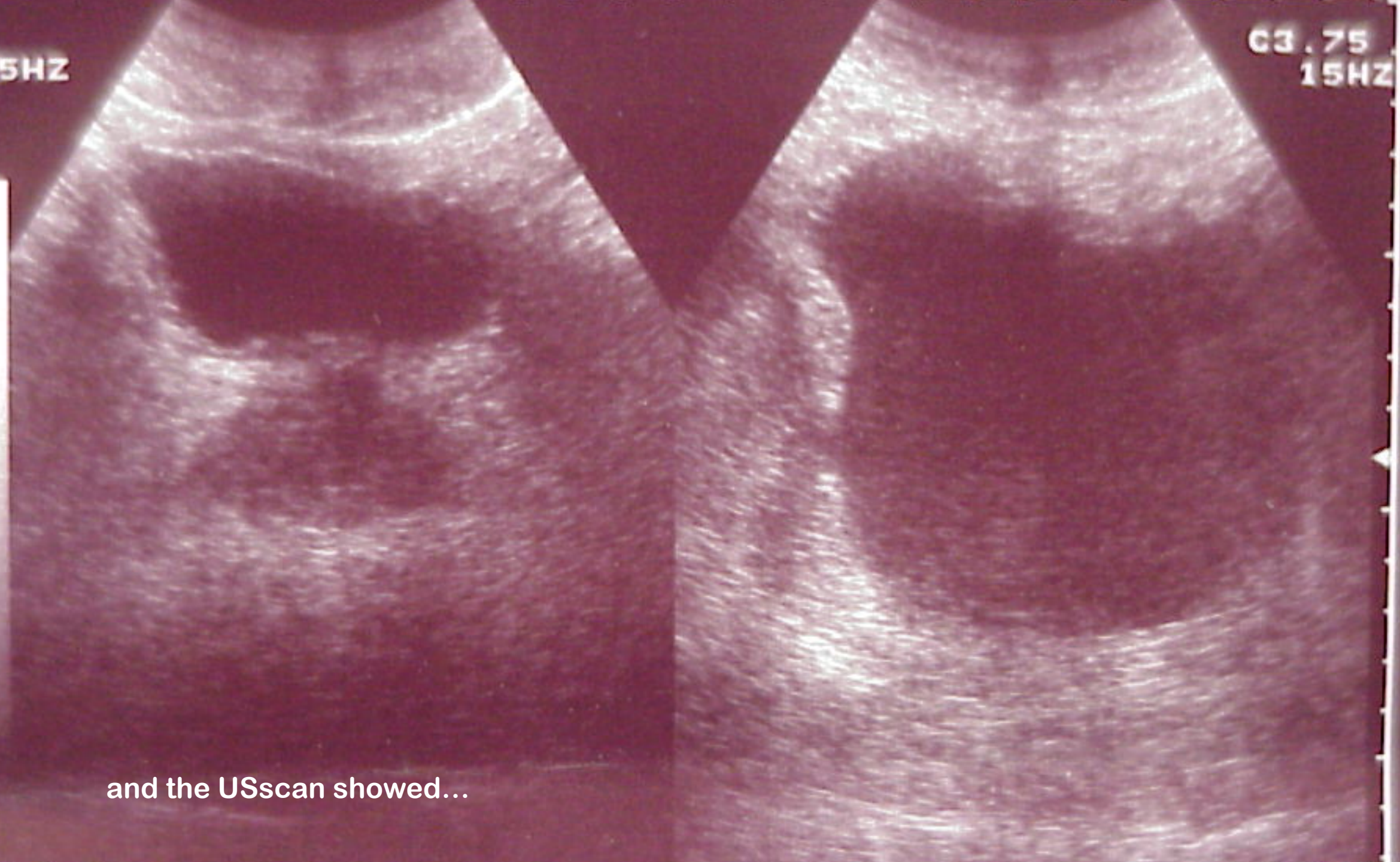
Fell while skiing on the 22nd March 2003, some pain at the left rib bow, went home. Early morning the day after, sudden abdominal pain going into the left axilla.

Abdomen tense, tachykardia, centralized, Hb 12g%...

15HZ

C3.75
15HZ

and the USscan showed...



15HZ

C3.75
15HZ

4/0
60/ 72
18. 60M

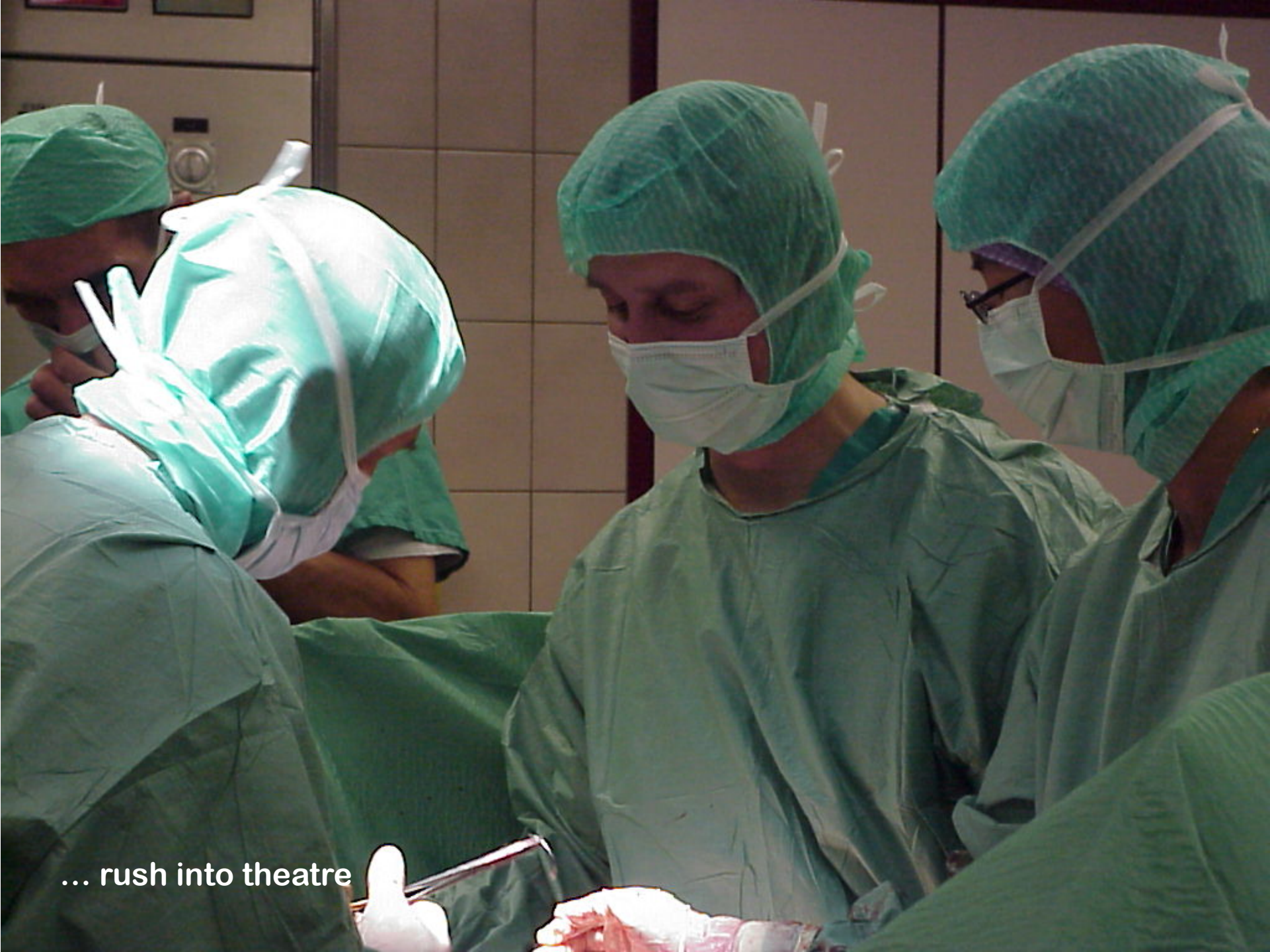4/0/1
60/ 72
18. 60M

15HZ

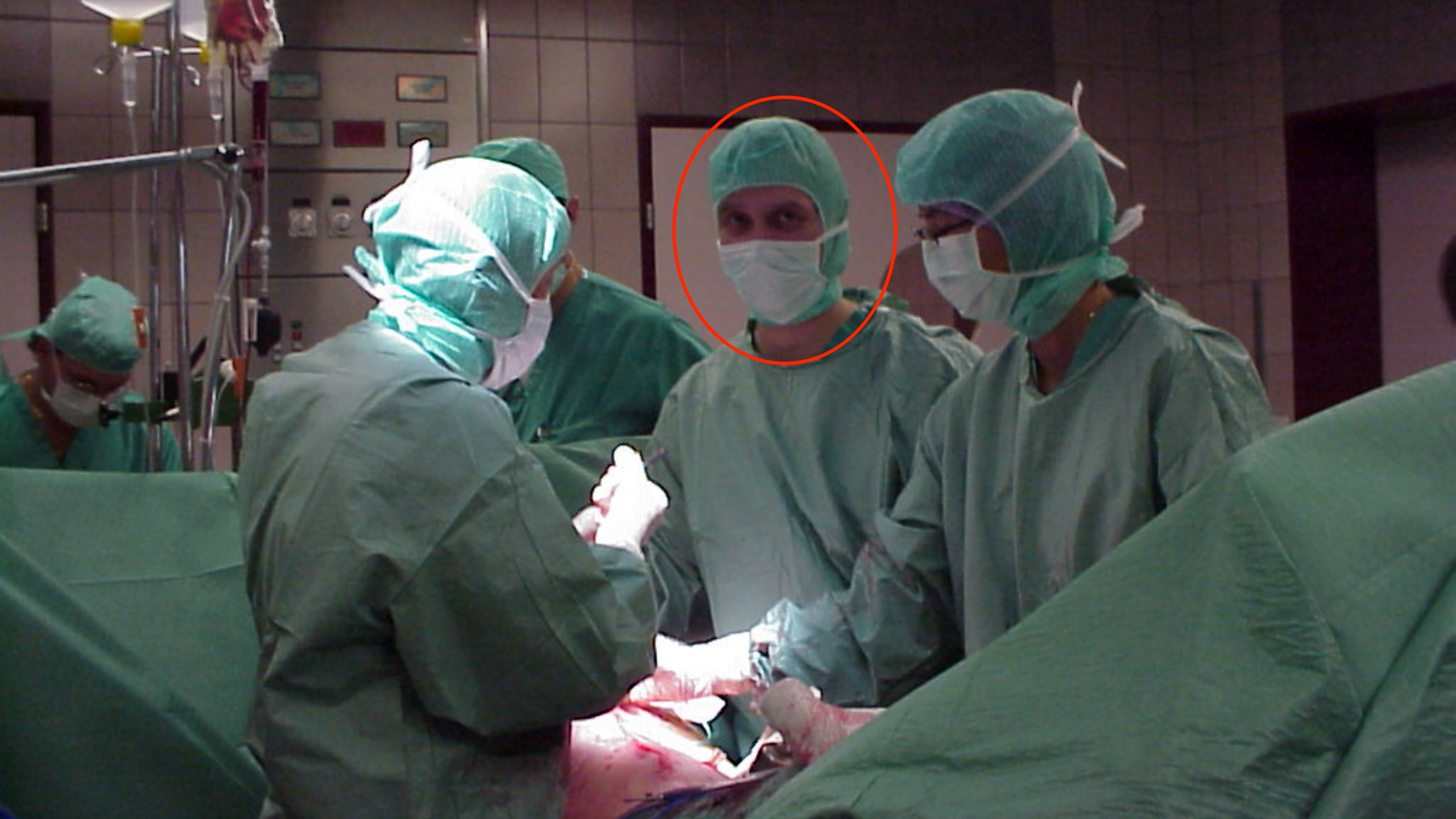C3.75
15HZ

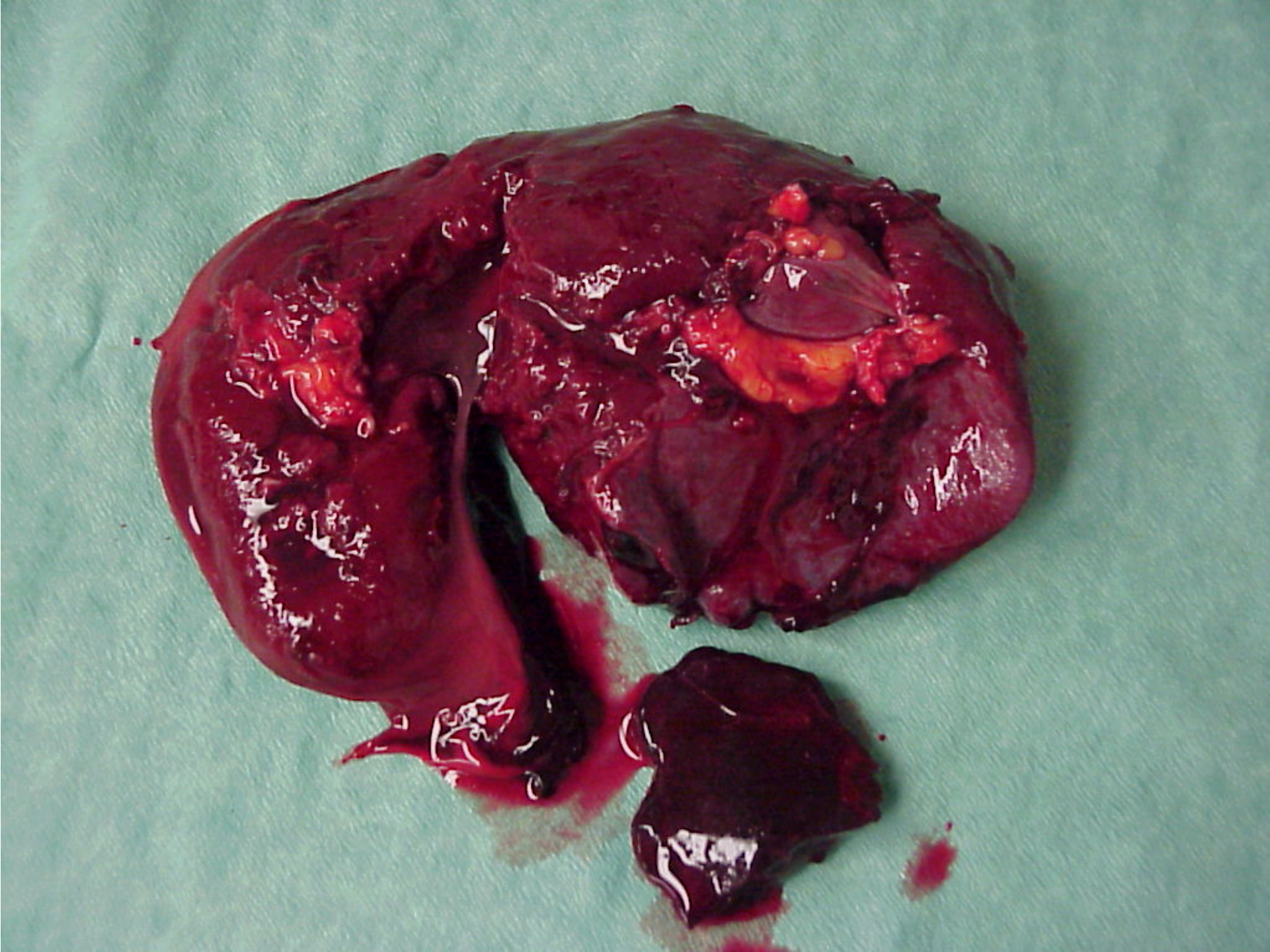
4/0
60/72

4/0/1
60/72



... rush into theatre





Oftentimes...

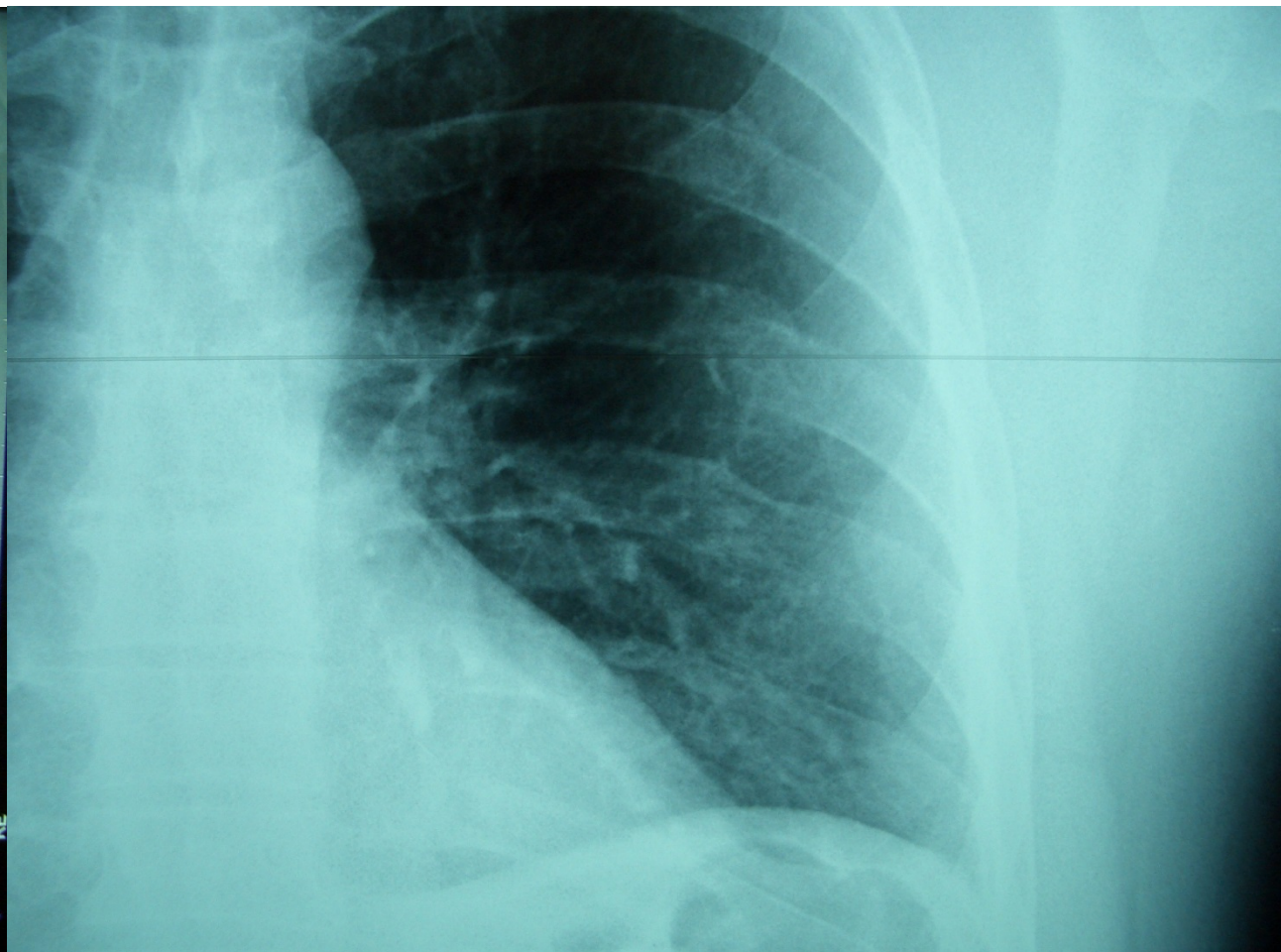
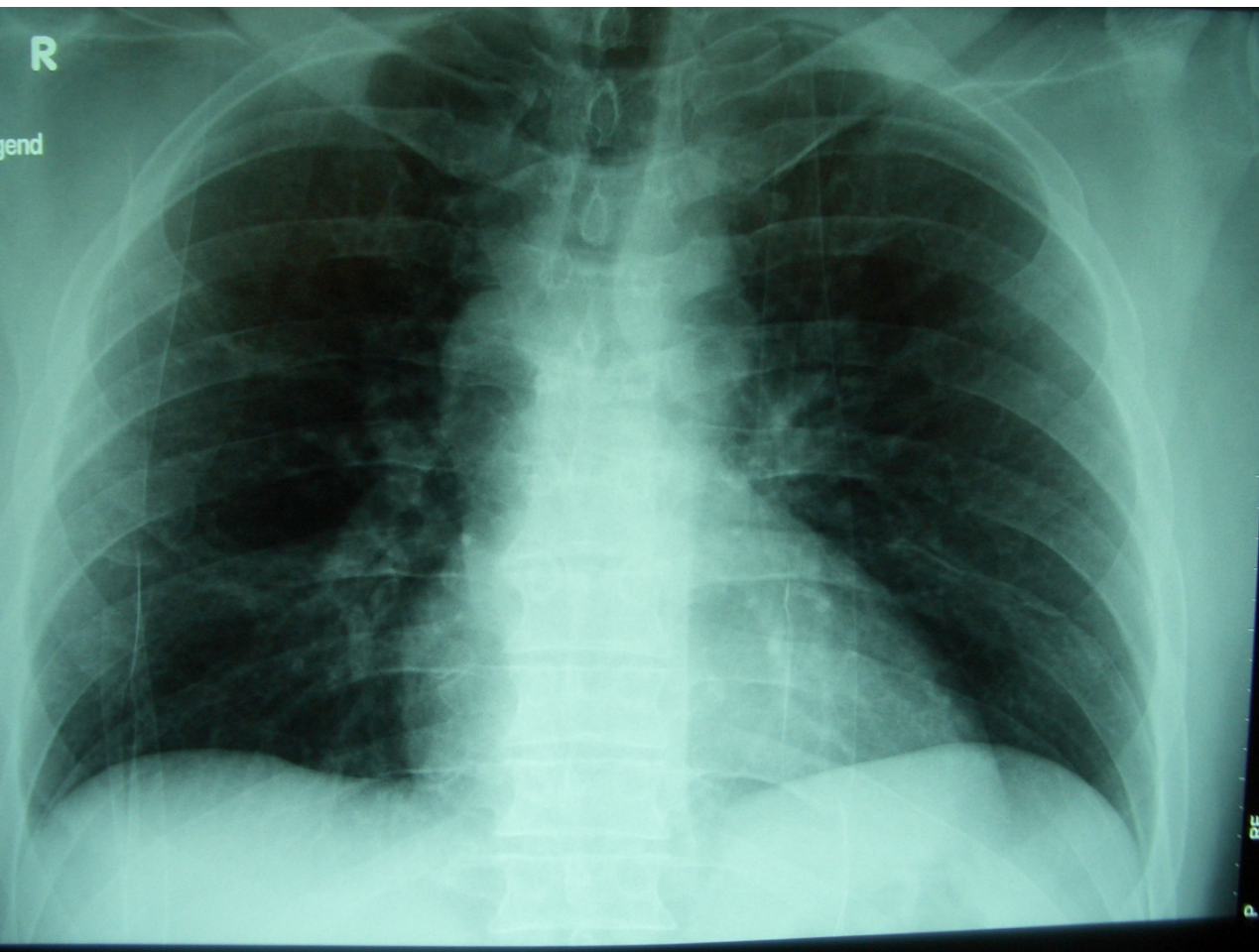
young, male – unmarried!

...and the children?

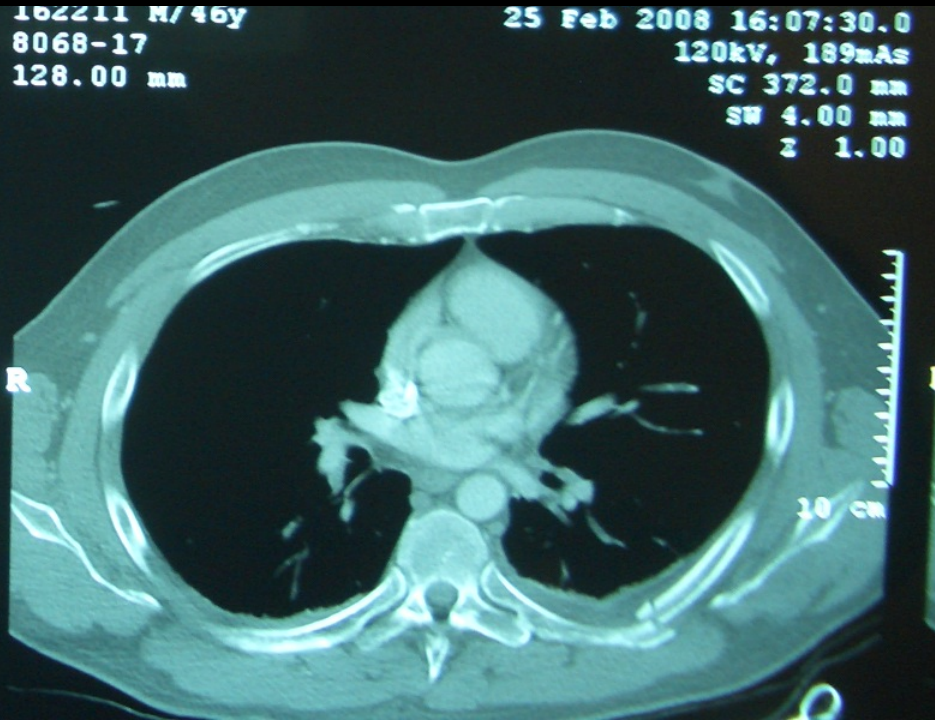
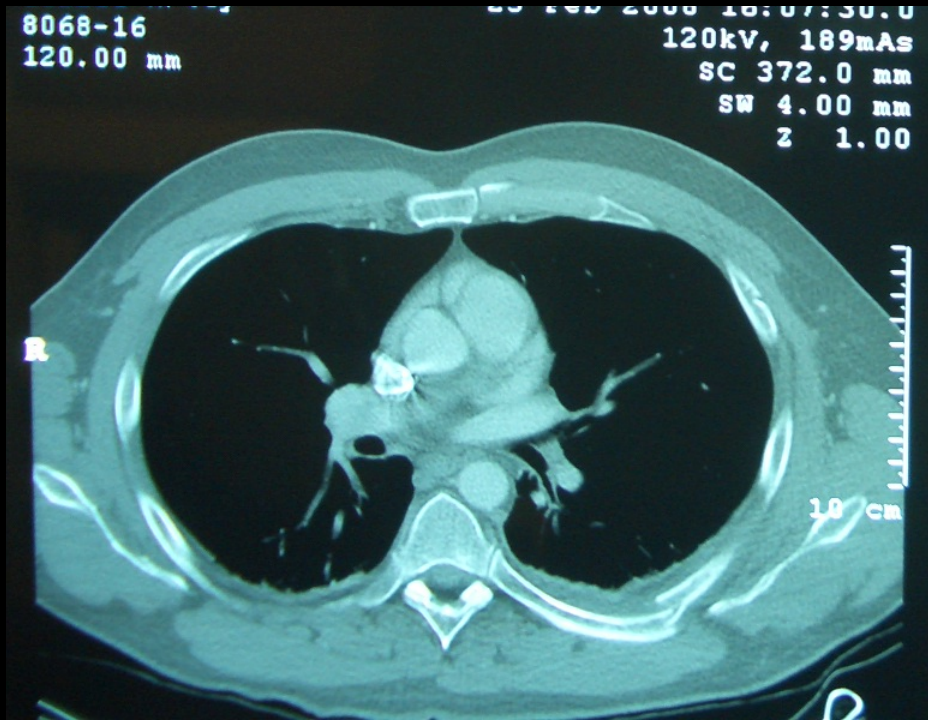
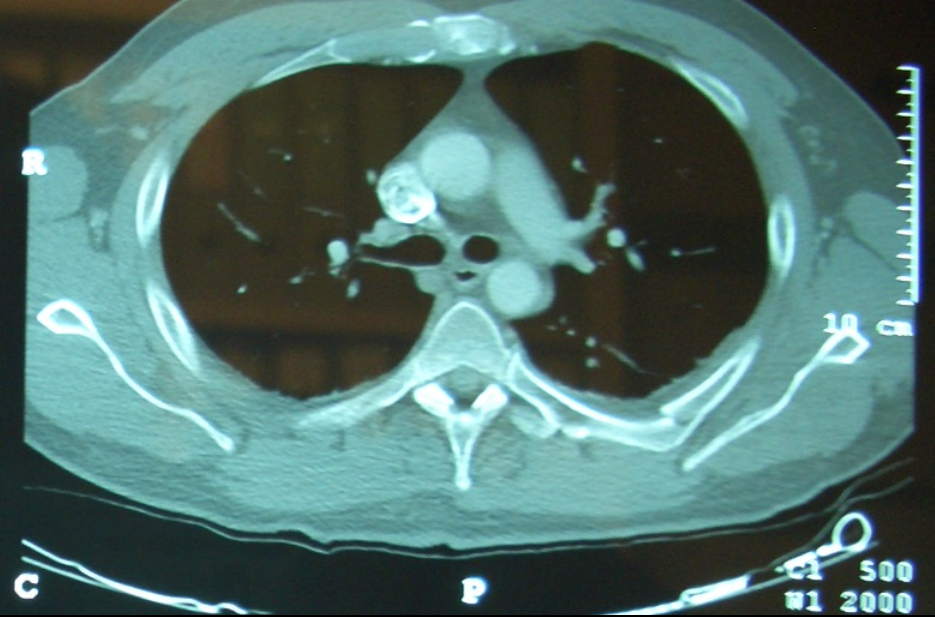
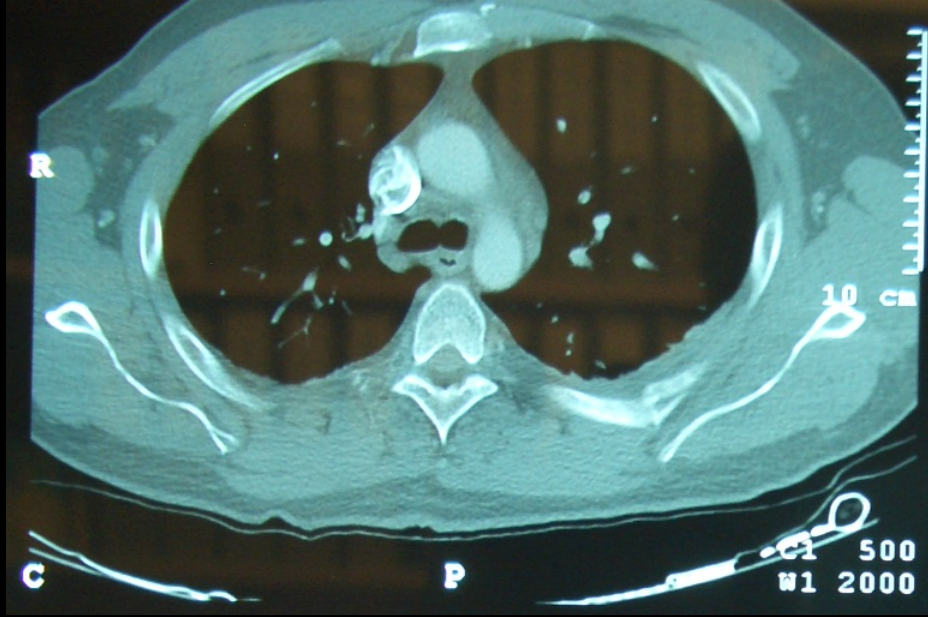
trunk injuries in snowboarding children, 6-21 years (n=39)

	male (29)	female (10)
chest	3	1
back	7	1
abdomen	18	1
pelvis	1	7

other injuries...



L. T. 46y, male, collision on the slope



aortic rupture (university of Berne)

4/ 22 patients with high-speed crashes

- all male
- 2 ski/ 1 snowboard/ 1 crosscountry
- classical interscapular back pain
- no intubation!
- minimal fluid

snowsport polytrauma patients



Polytrauma:

2013/ 2014

2014/ 2015

2015/ 2016

32 patients

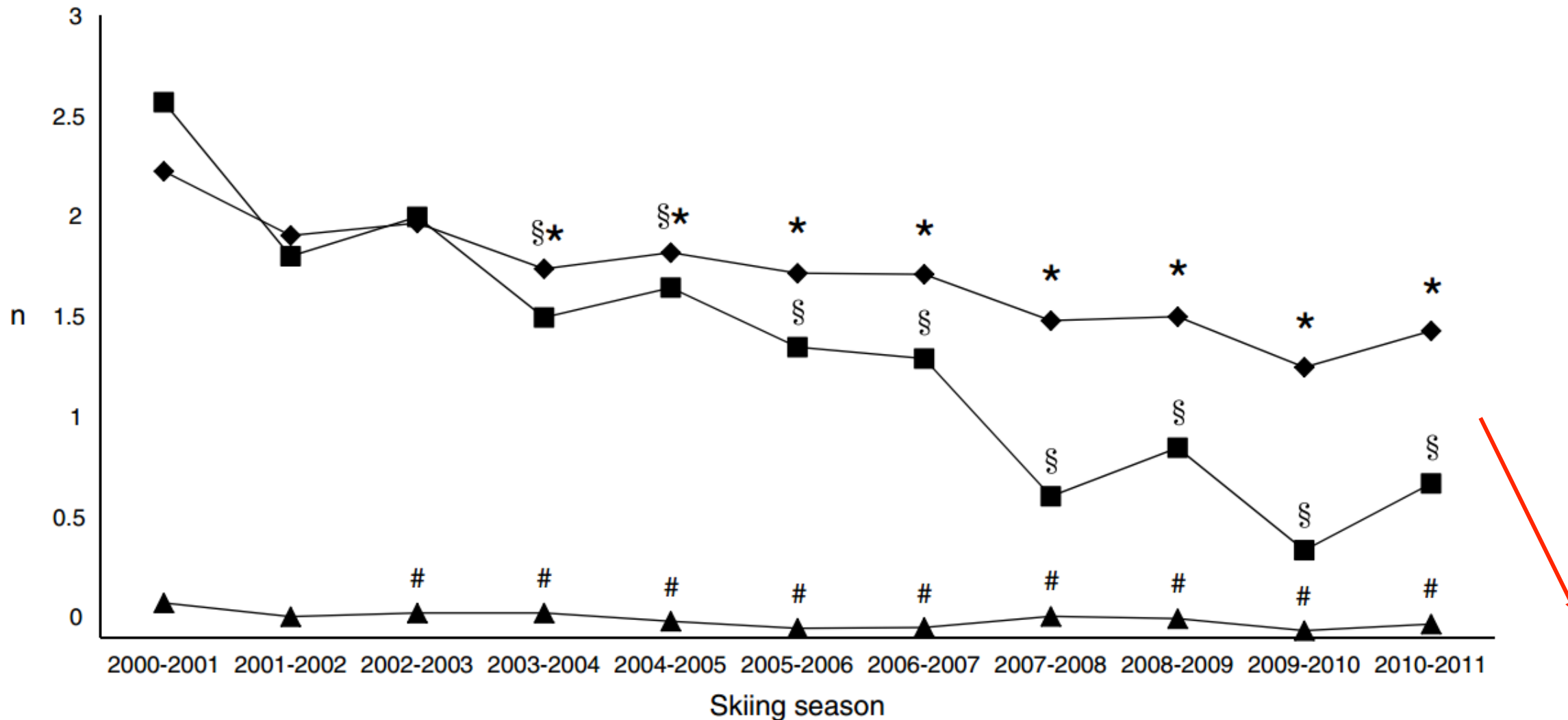
24 patients

26 (as of today)

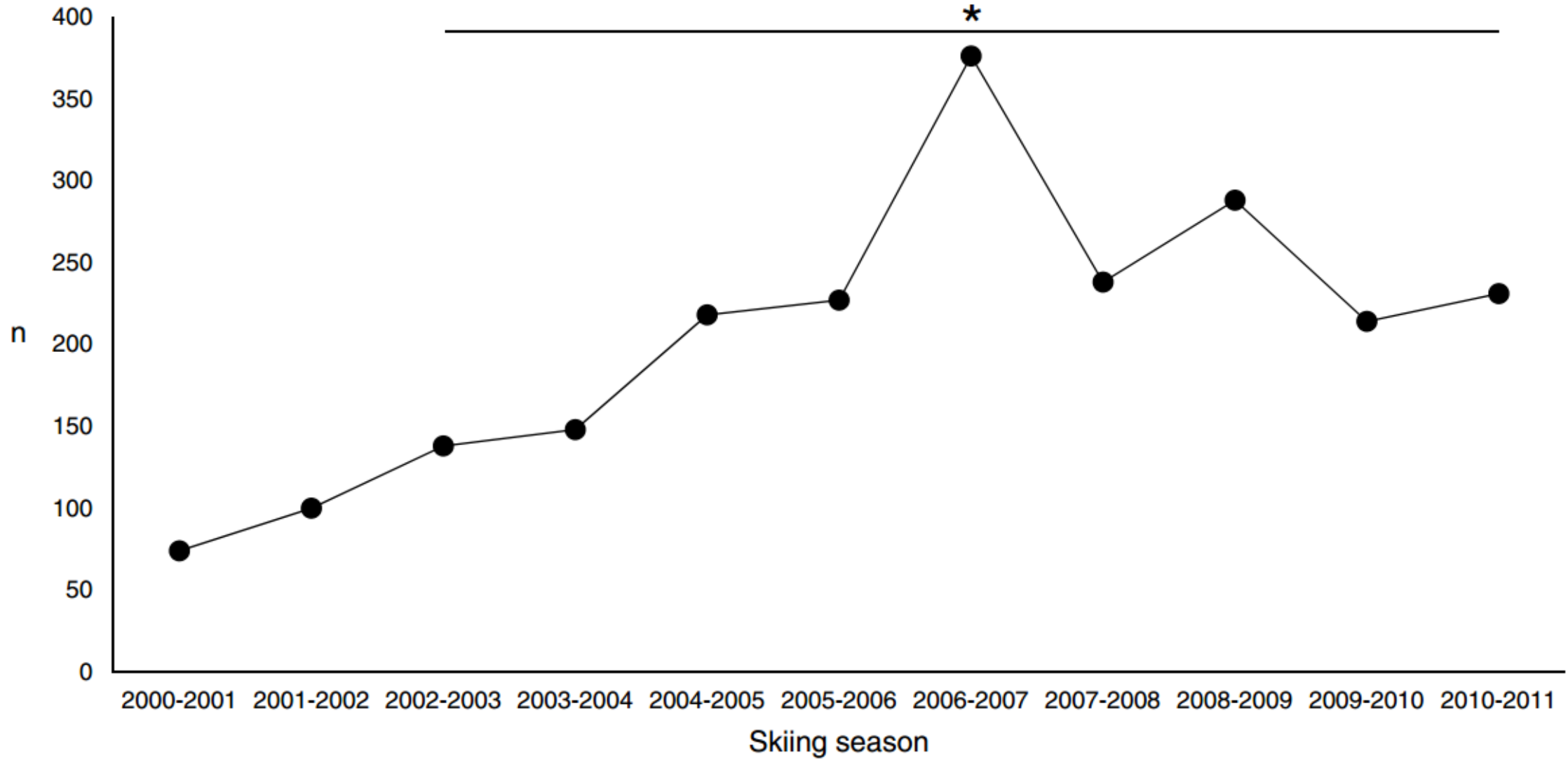
imaging



Trauma Center Innsbruck



- ◆ Mean number of radiological modalities/skiing accident victim at hospital admission
- Mean number of anatomical regions/skiing accident victim assessed by conventional radiography at hospital admission
- ▲ Mean number of acute sonographies/skiing accident victim at hospital admission




● Total number of CT examinations due to skiing accidents

„...radiological evaluation in patients admitted from skiing accidents has changed during the last decade and skiing accidents victims need full-body diagnostic radiological attention in their casualties“

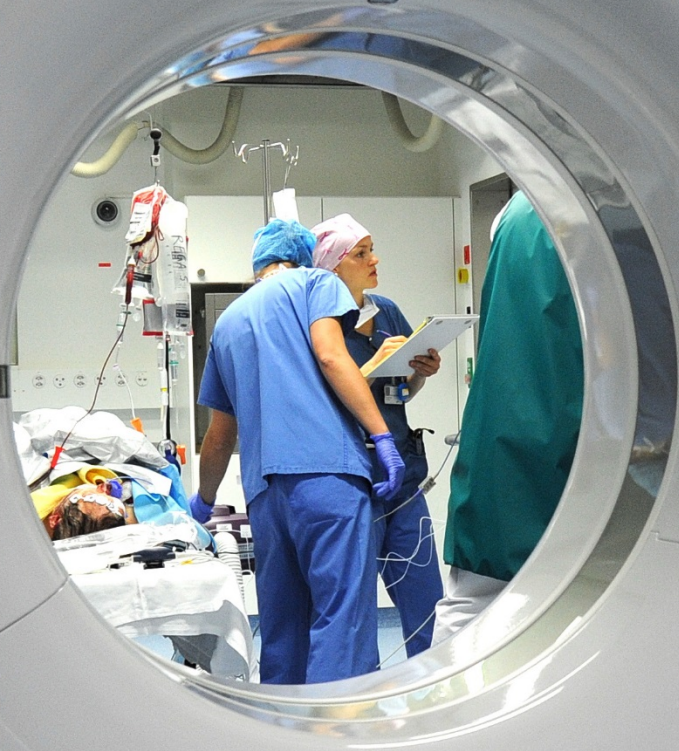

Dr. med. Thomas Müller, head emergency department, Trauma Center, Chur

SIEMENS



SOMATOM
Definition Edge





**several
option to
finish this
talk...**



PAUL WALKER
VIN DIESEL
MICHELLE RODRIGUEZ
JORDANA BREWSTER

THE FAST AND THE FURIOUS

SKI



FASTER THAN
GRAVITY



back to the past...

**...no unmarried males on
the slope!**

the end