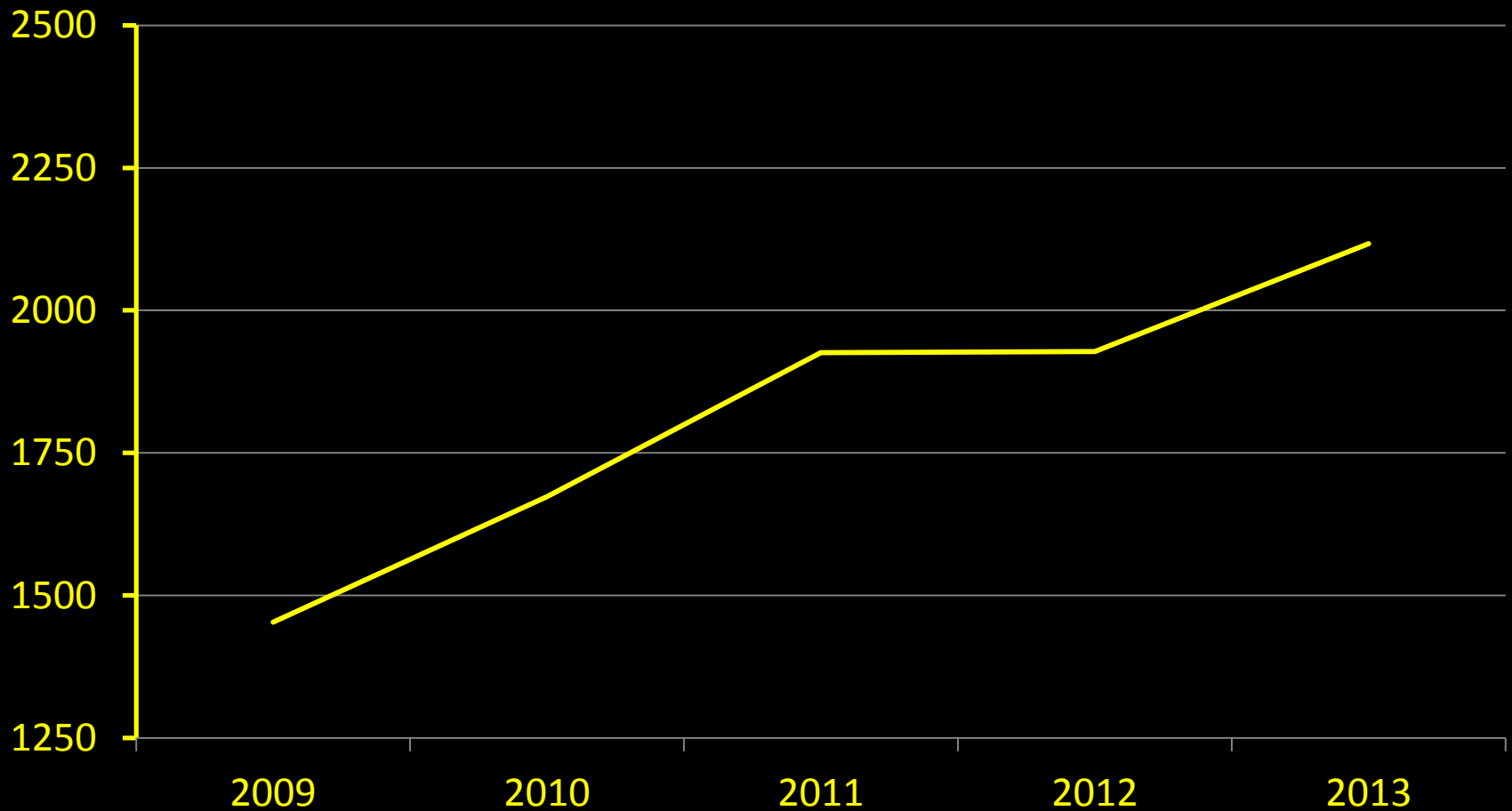


# *Shoulder injuries in Wintersports*



LKH Hall in Tirol Department of Traumatology and Sportsmedicine  
Dr. Dehbalaie Schahin , Head Prim Dr. A. Genelin

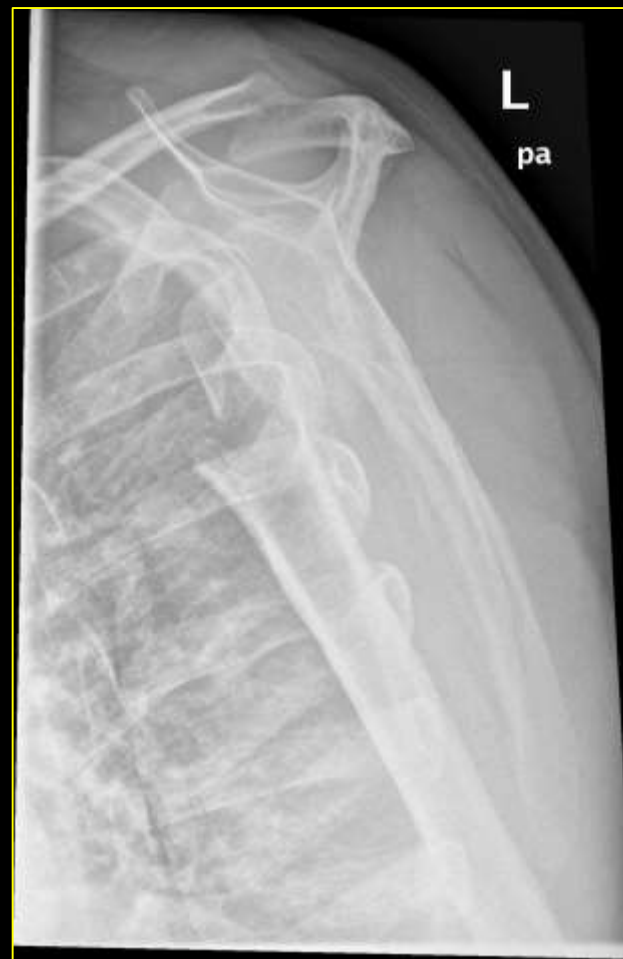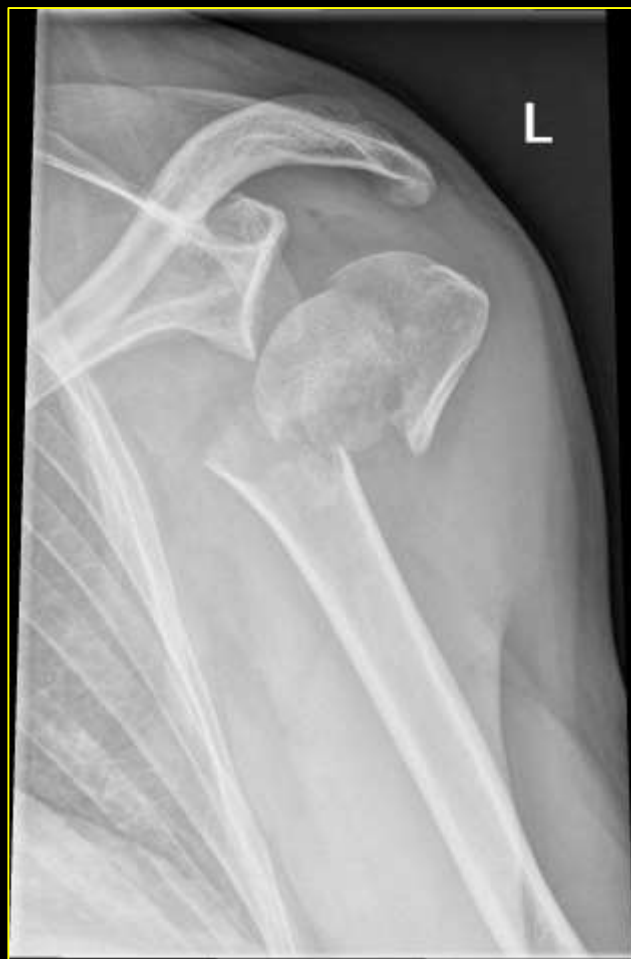# Increase in Shoulder injuries



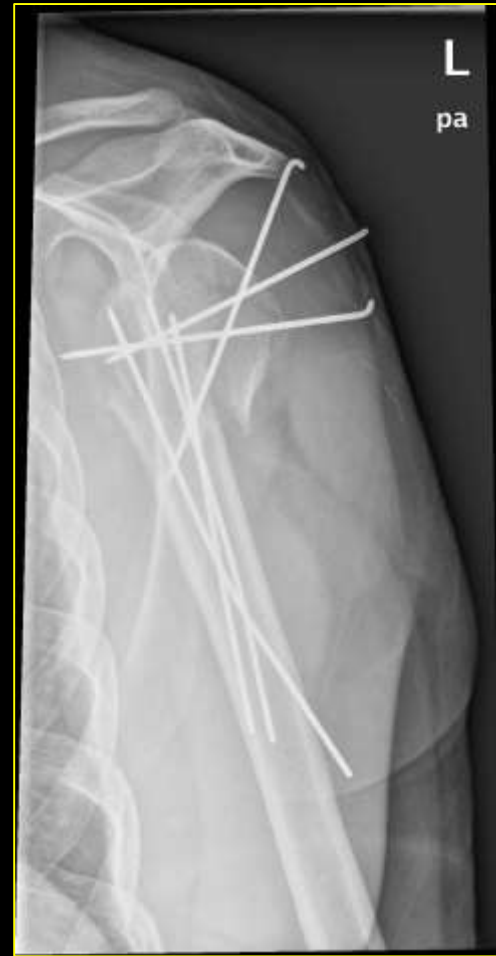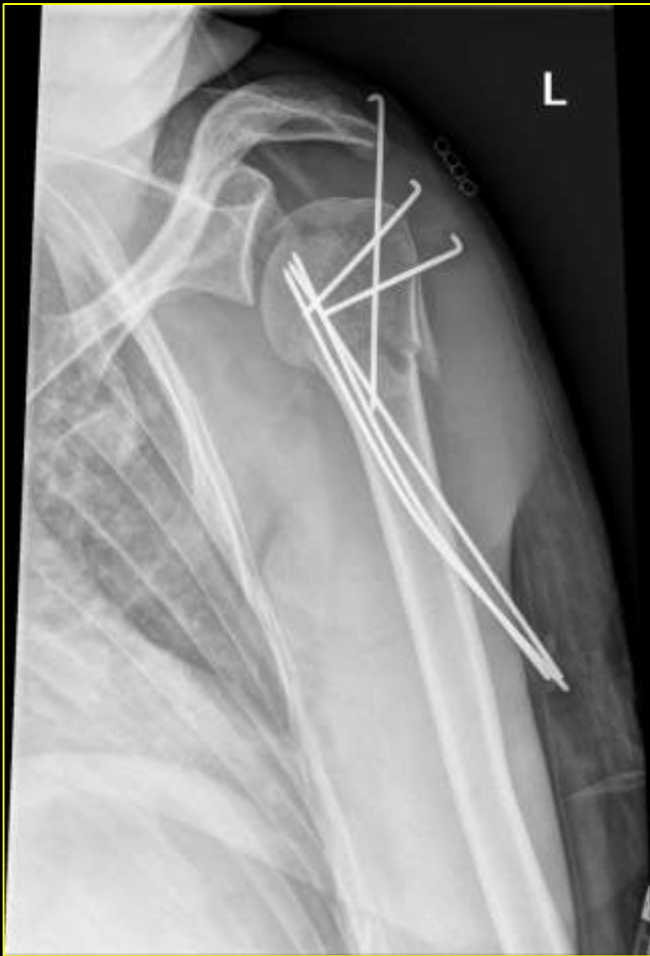# Shoulder injuries still a challenge

- **Implant:**  
K-wire, IMC ,Plate, Nail, Shoulder prothesis
- **Timing:**  
immediate or planned surgery
- **Outcome:**  
? correct anatomy & good function ?

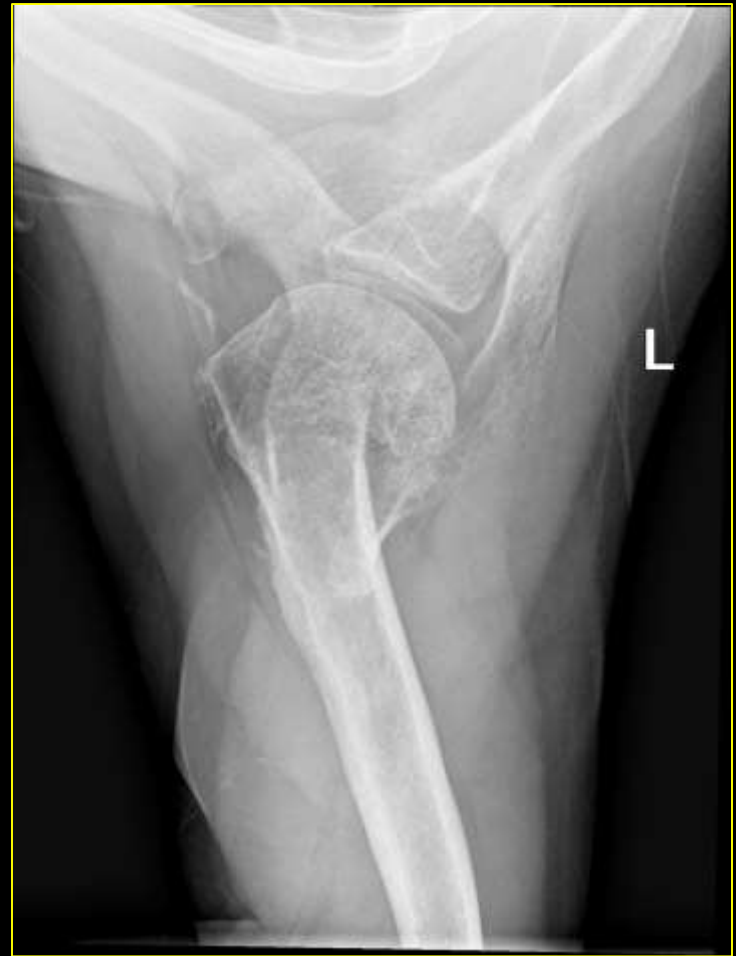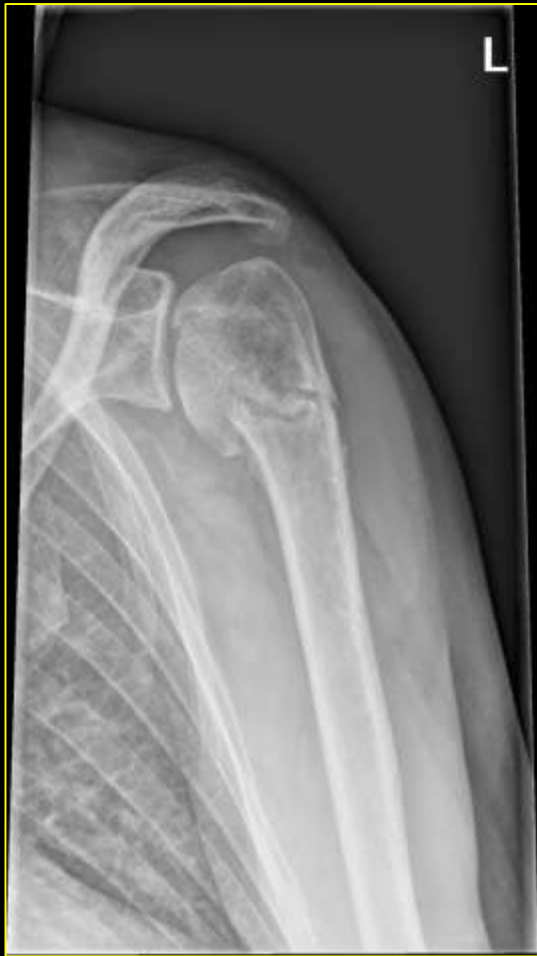# Case 1: 44 male



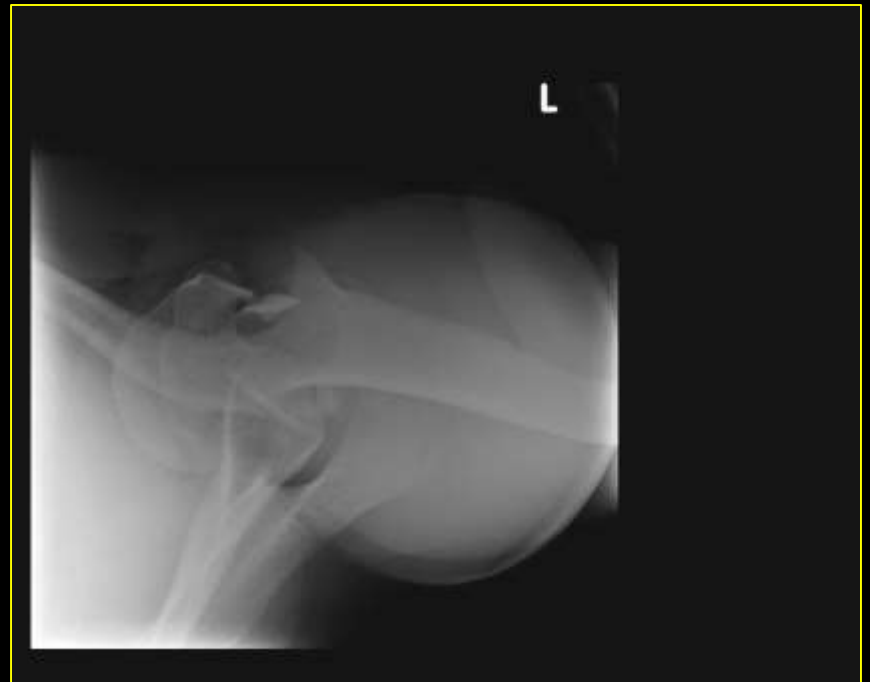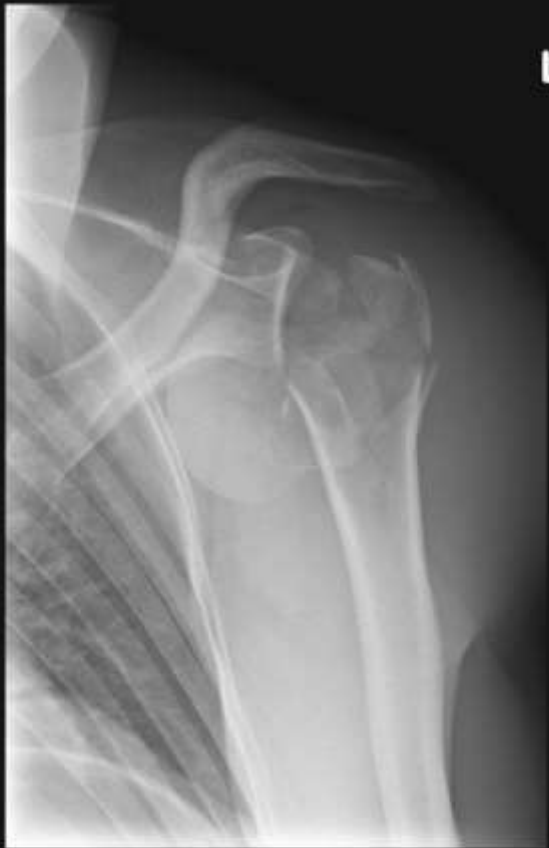# post surgery



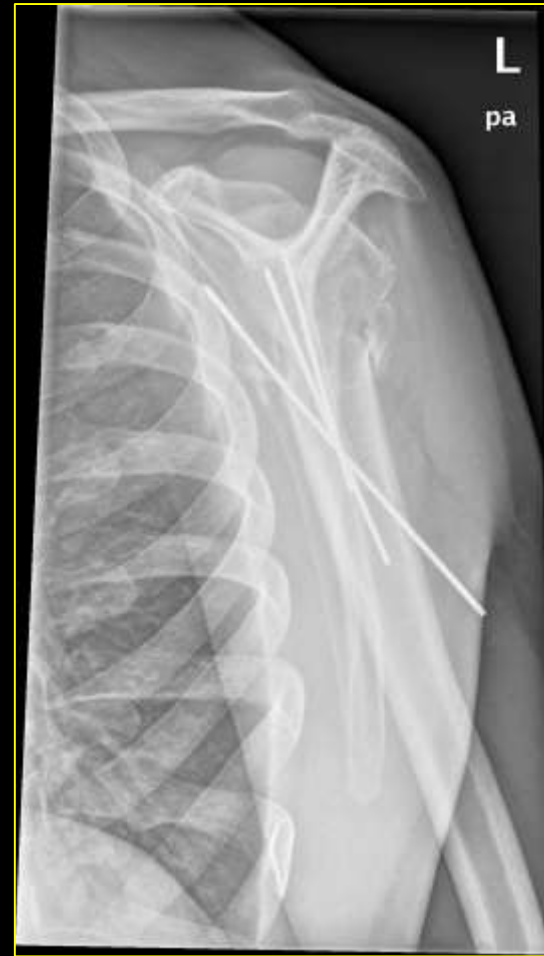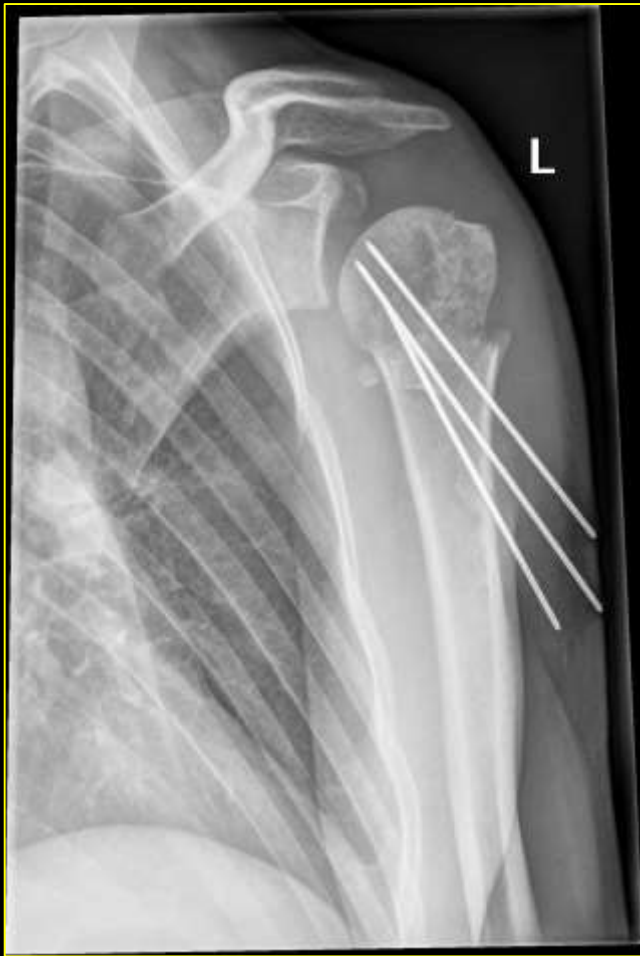# result



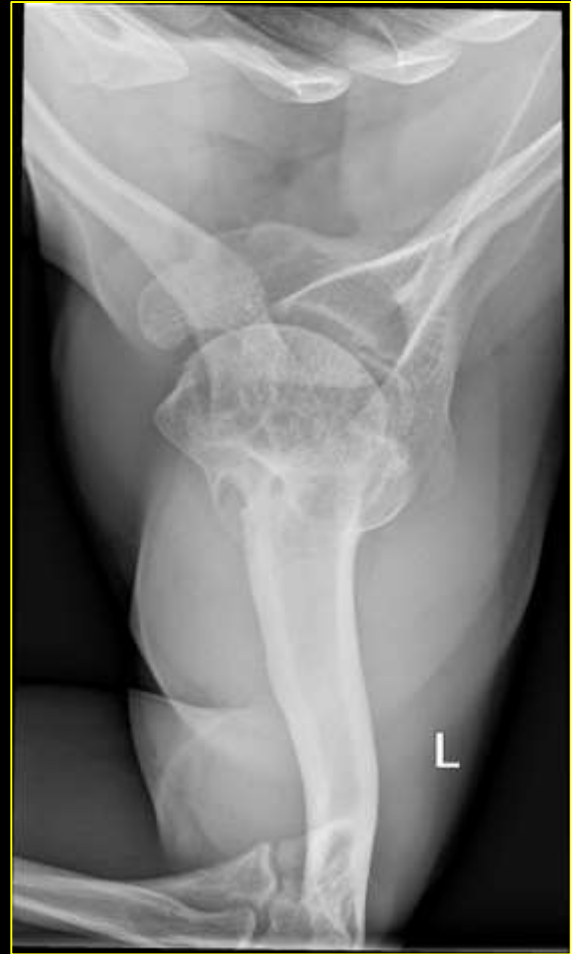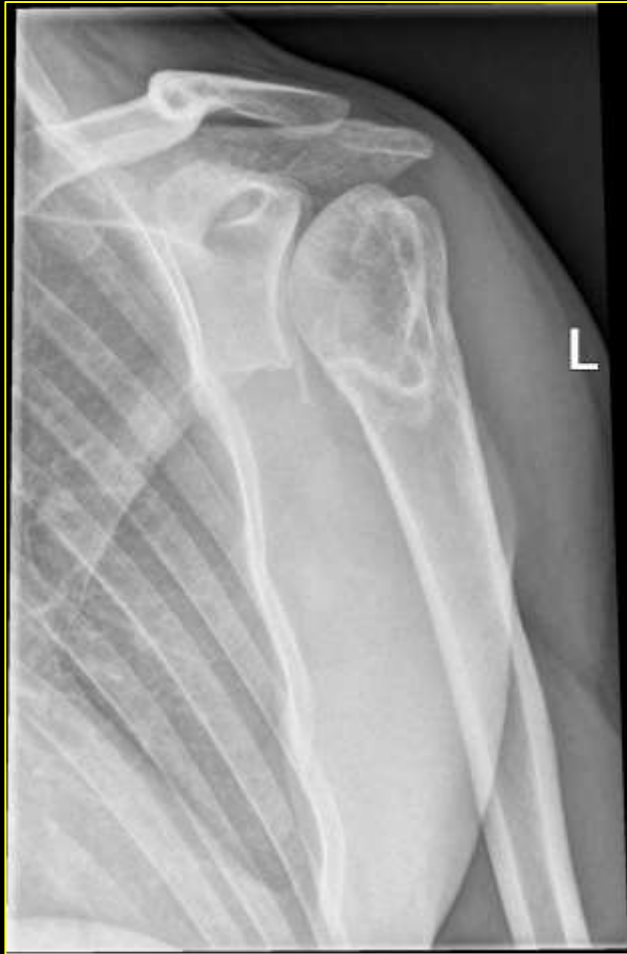## Case 2: 35 male



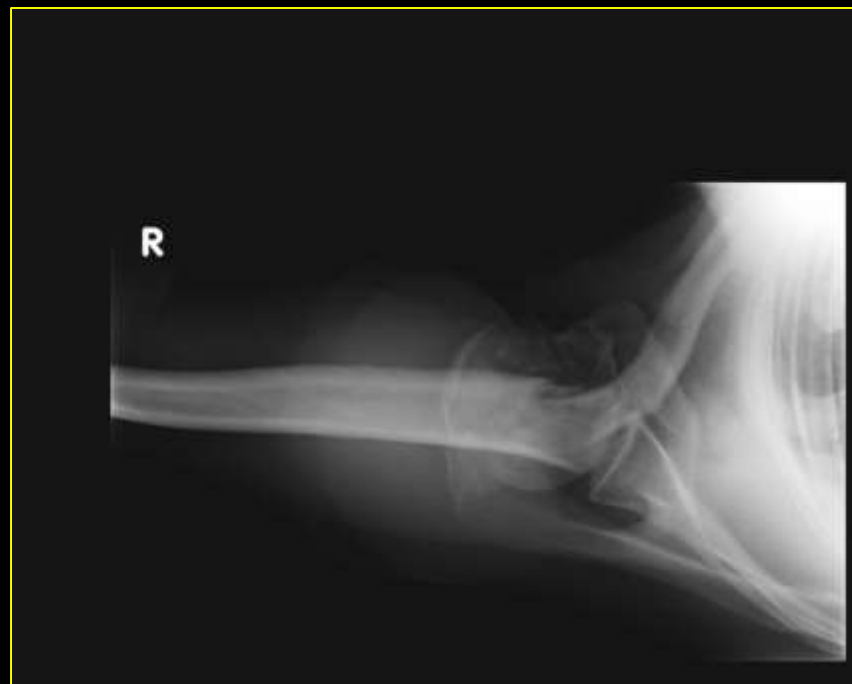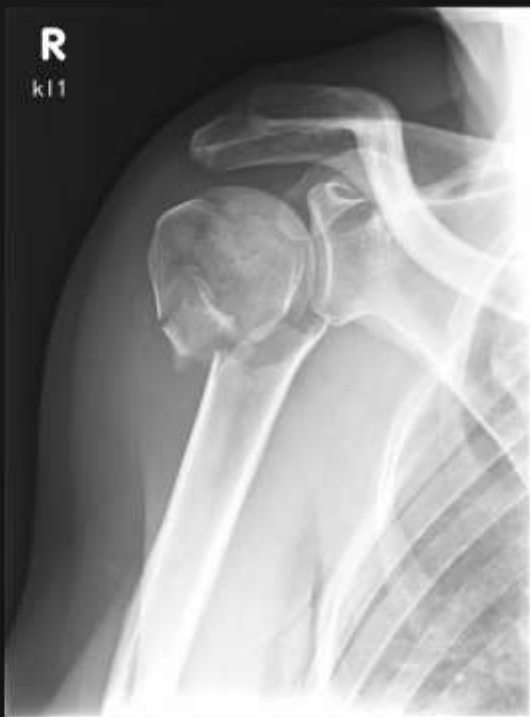# post surgery



# result

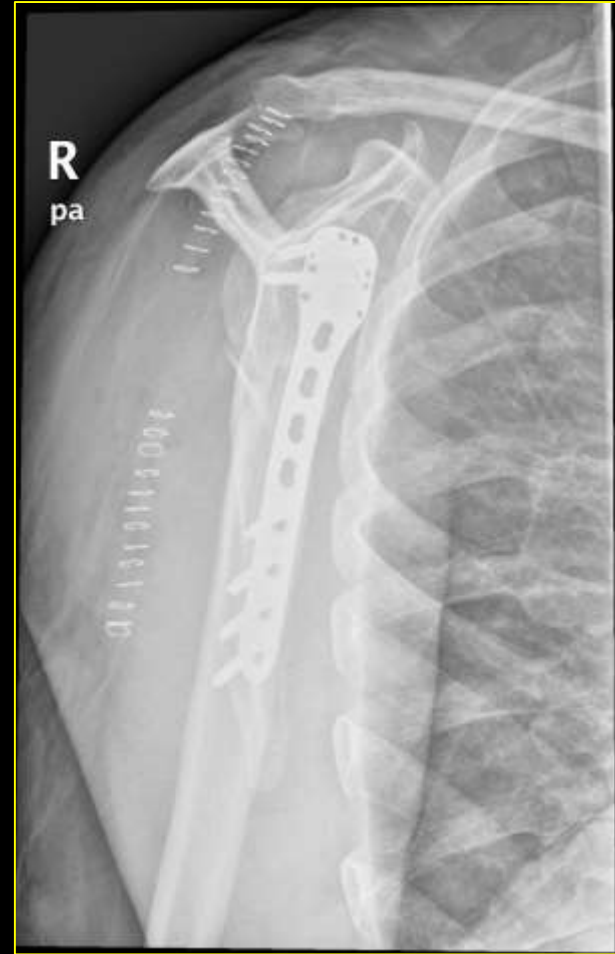
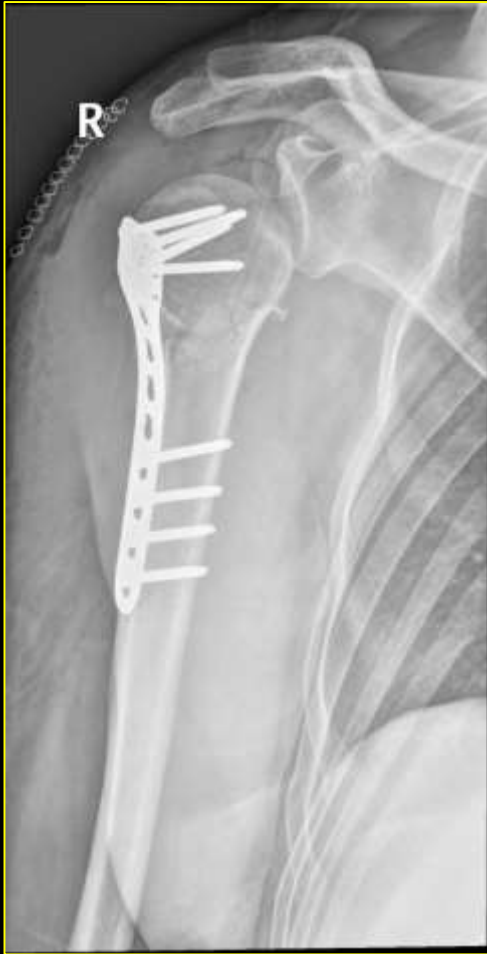

# Case 3: 60 male

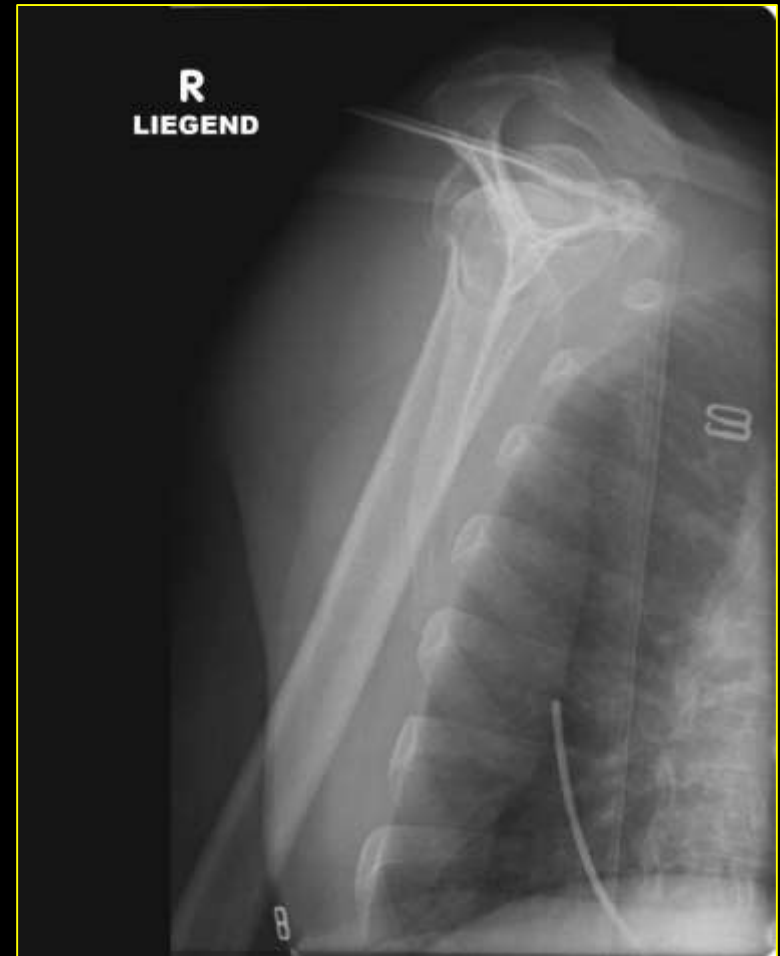
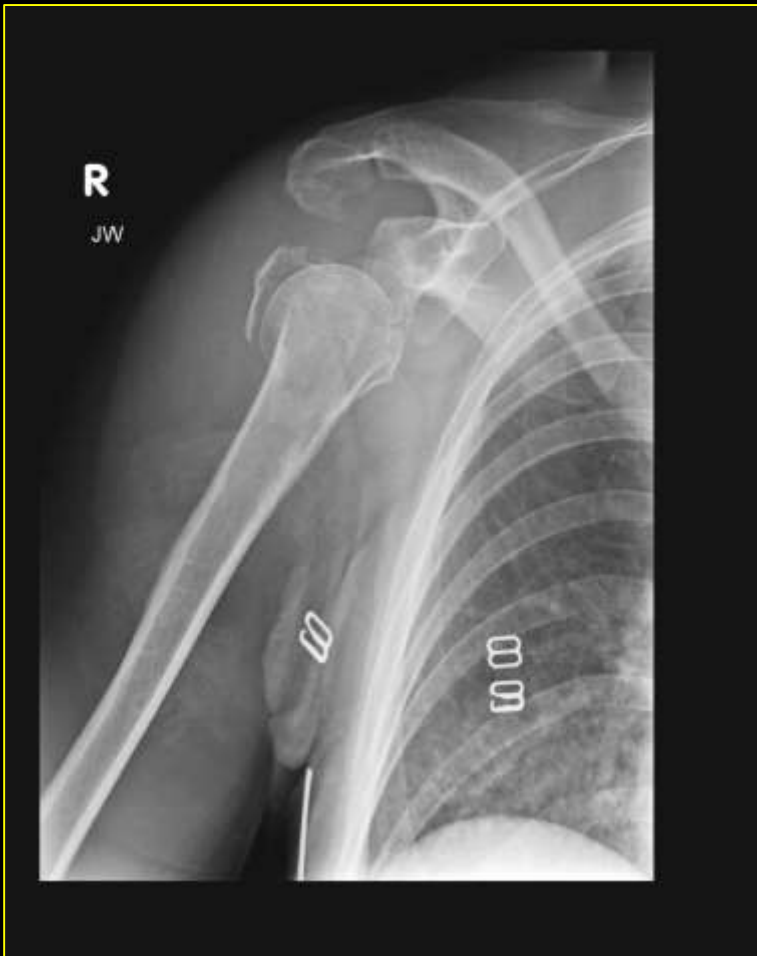


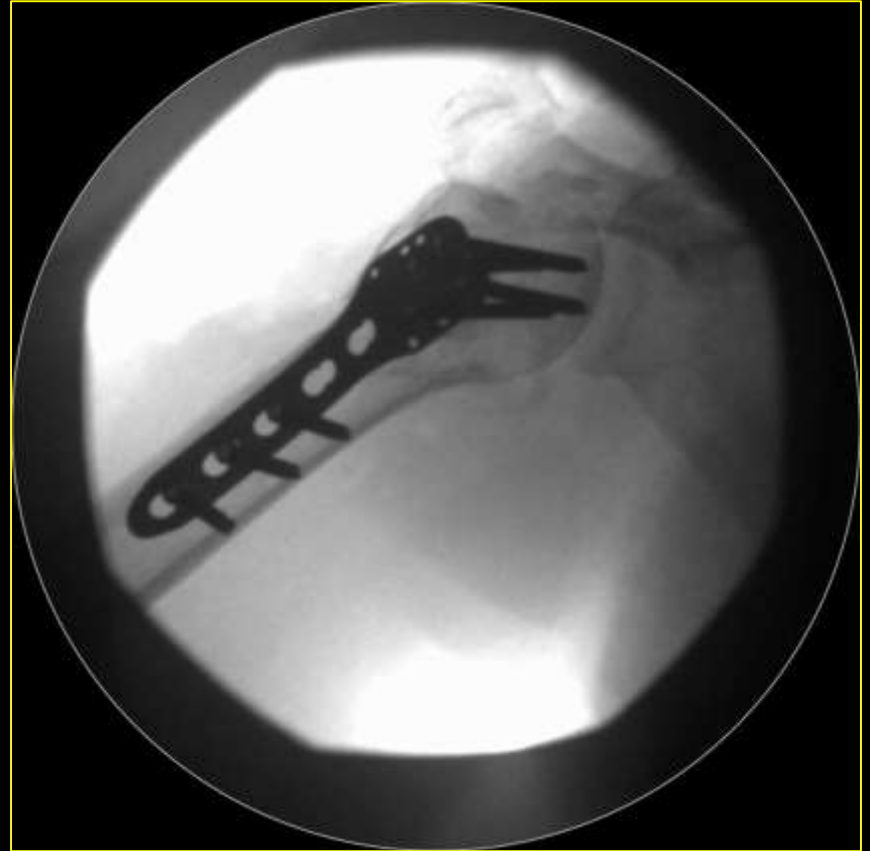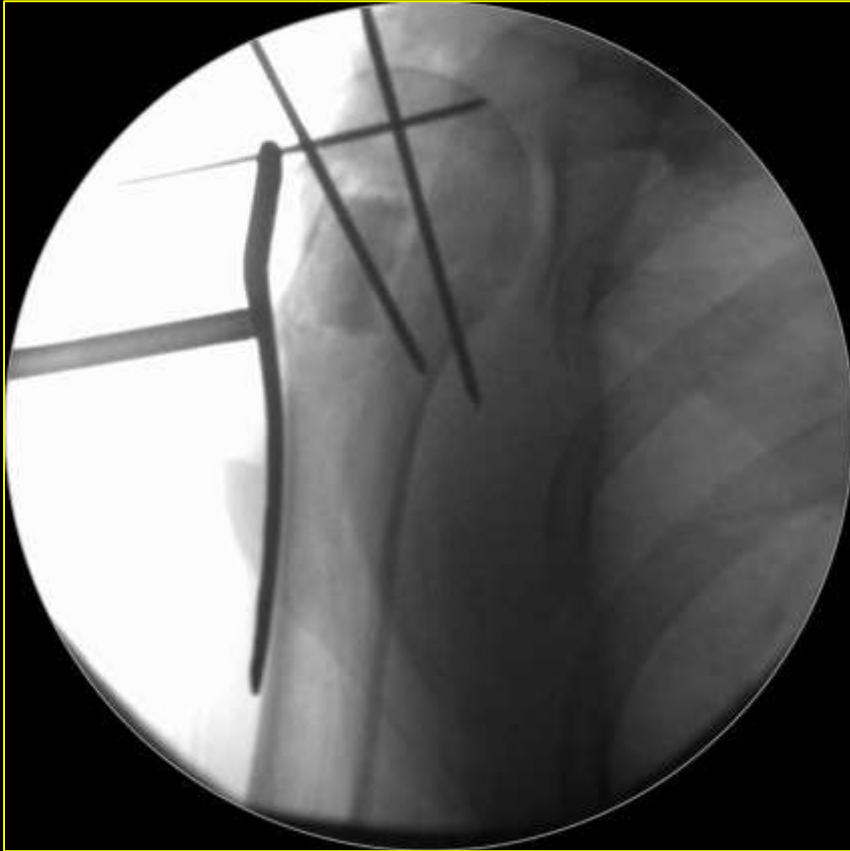# result

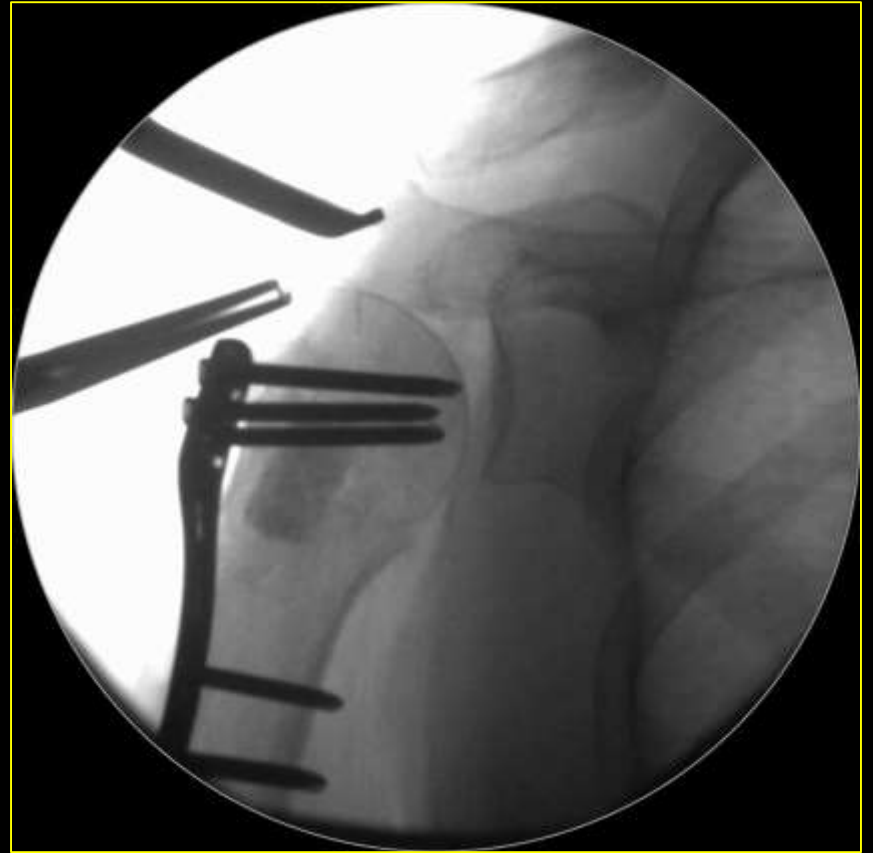
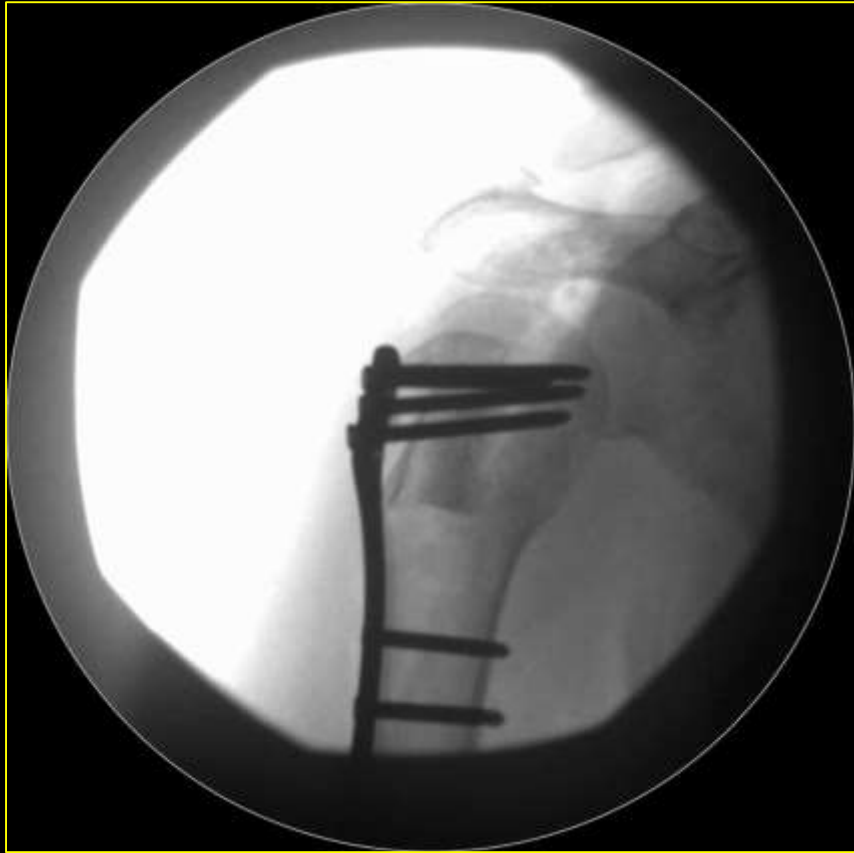


# Case 4: 55 female

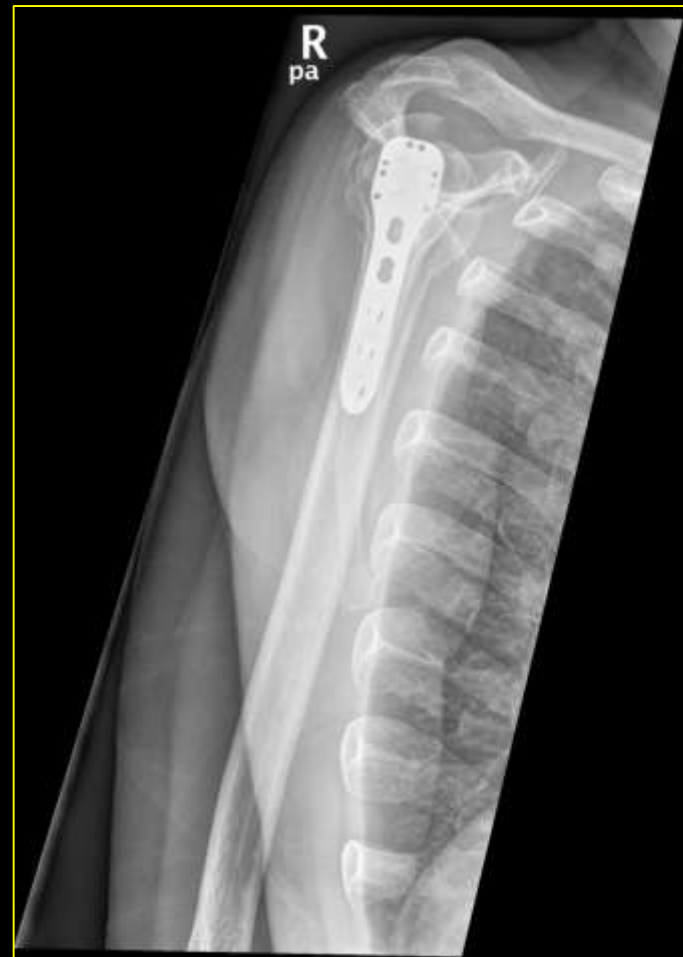
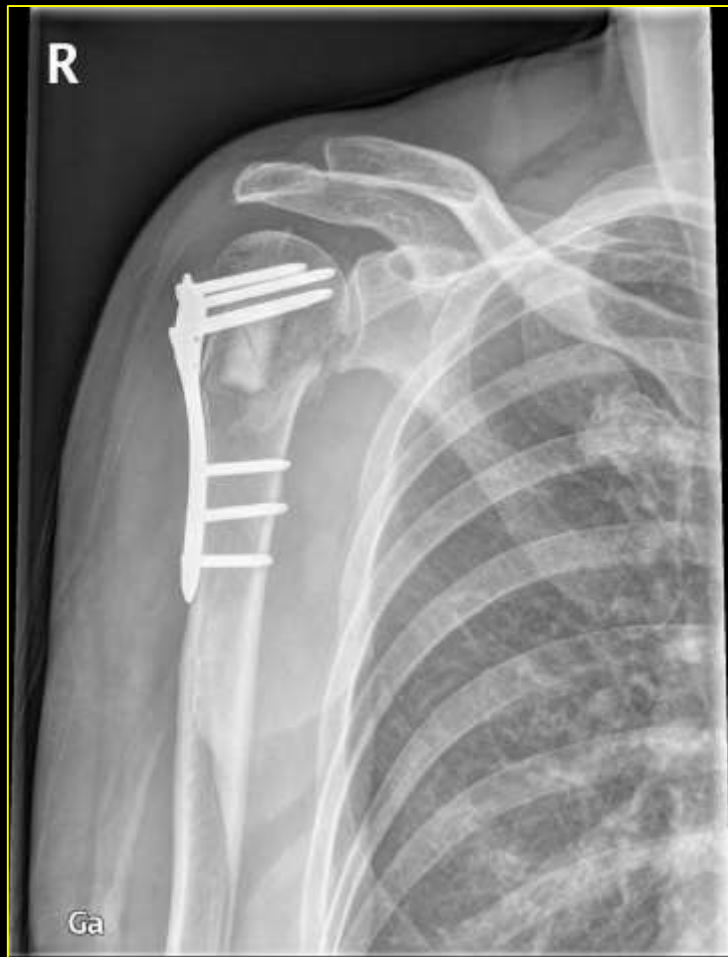
# surgery images

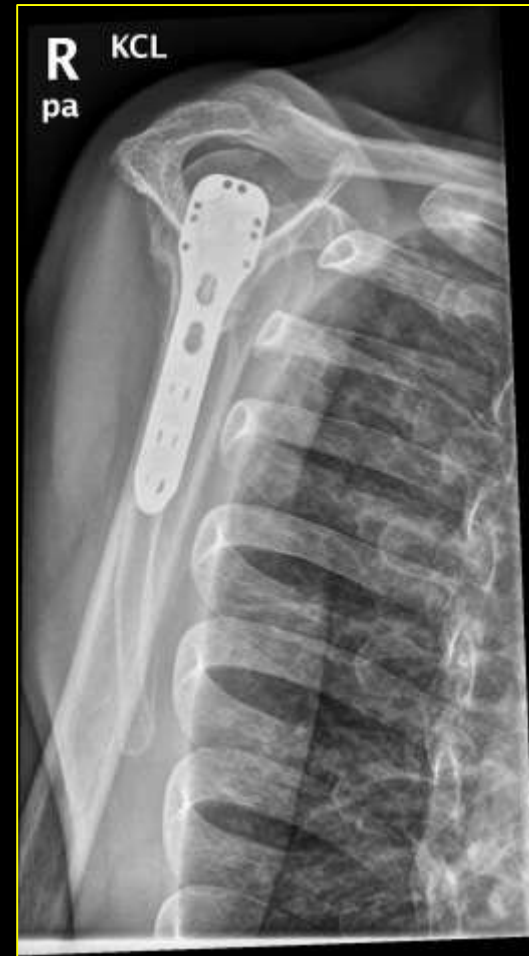
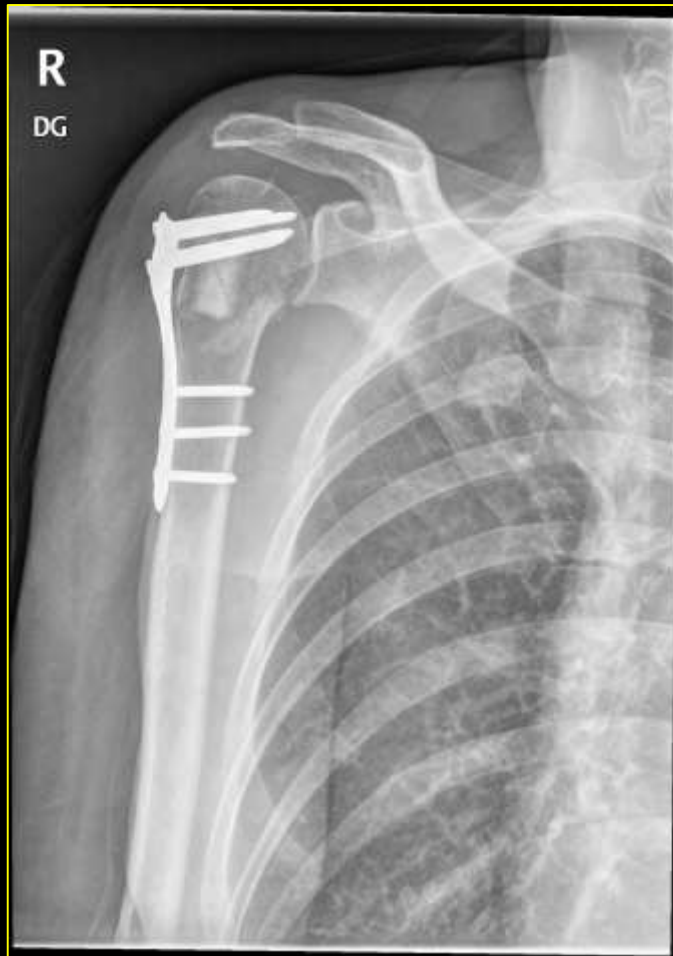


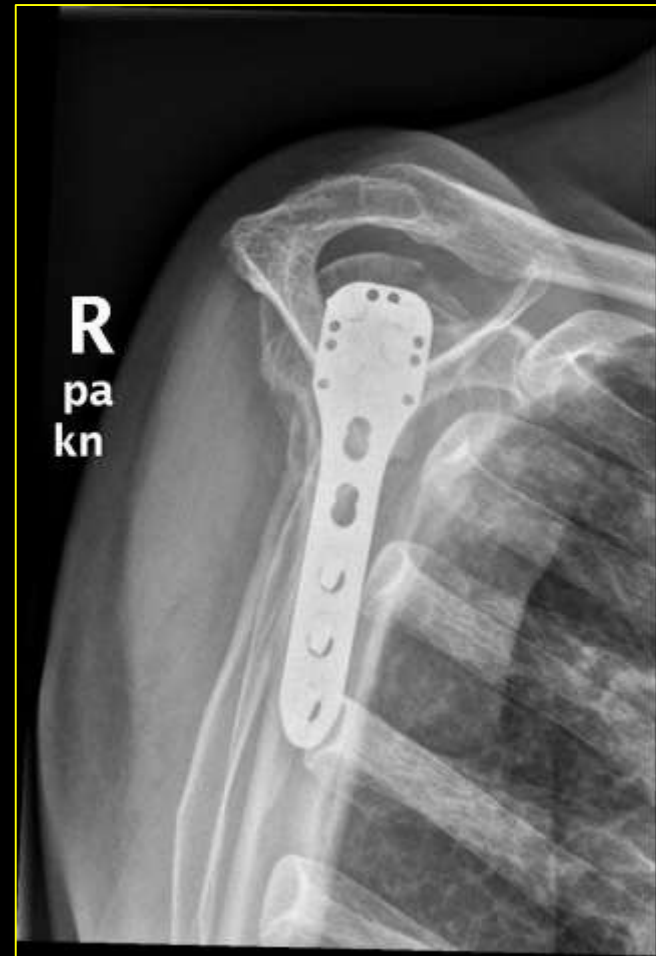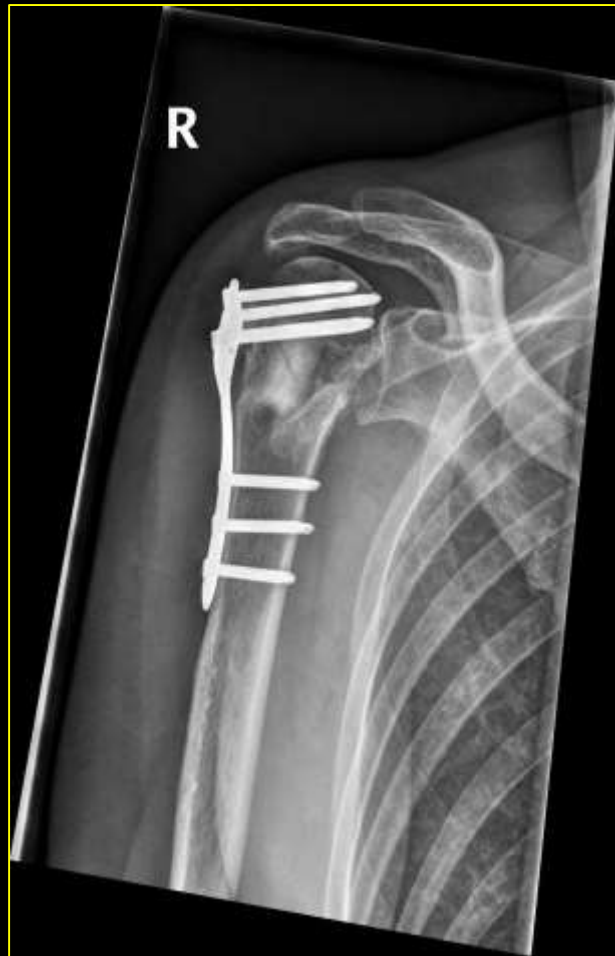# after surgery



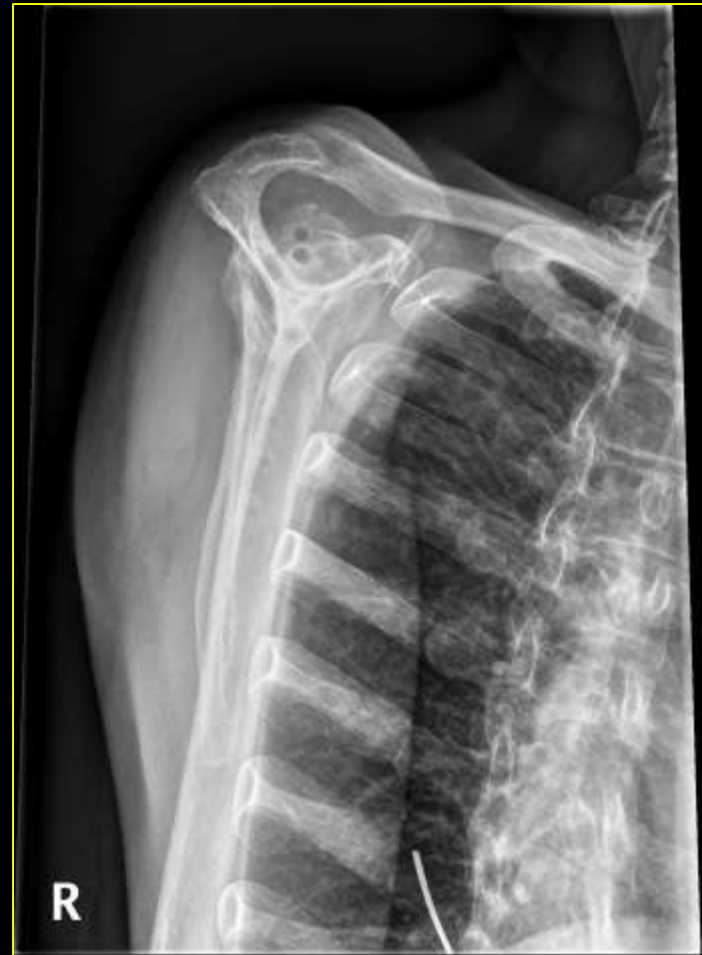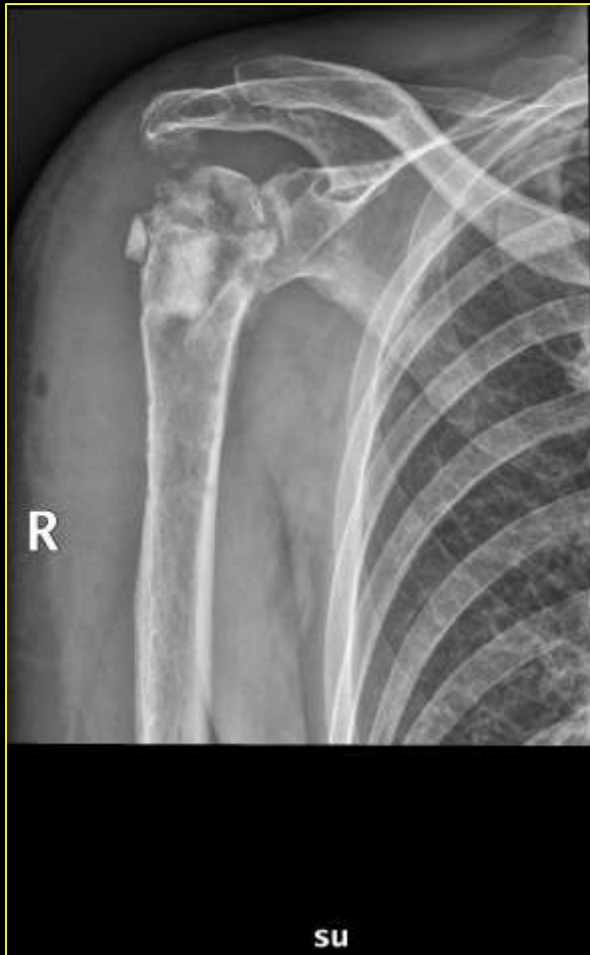# 3 months post surgery



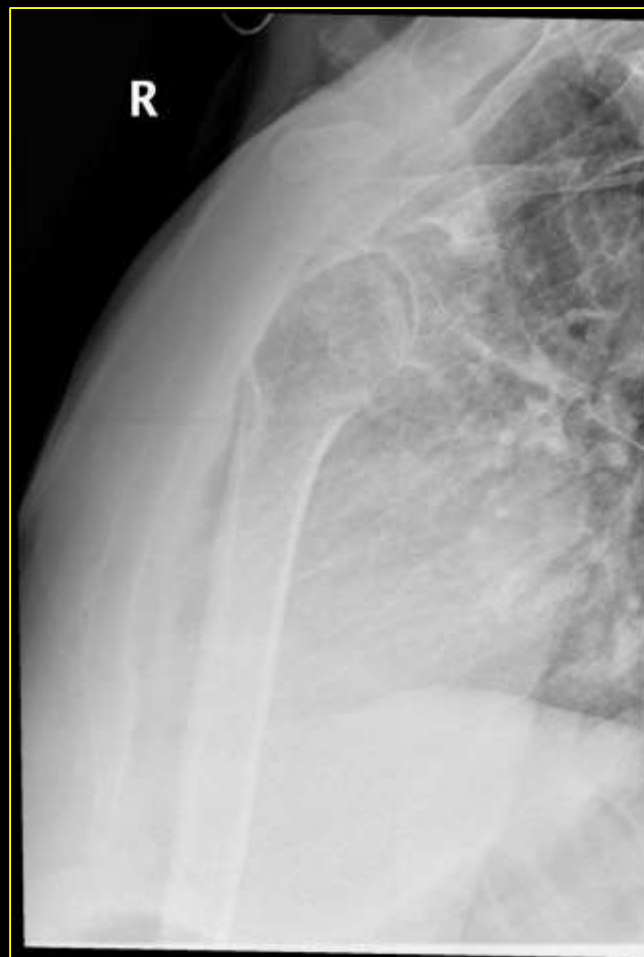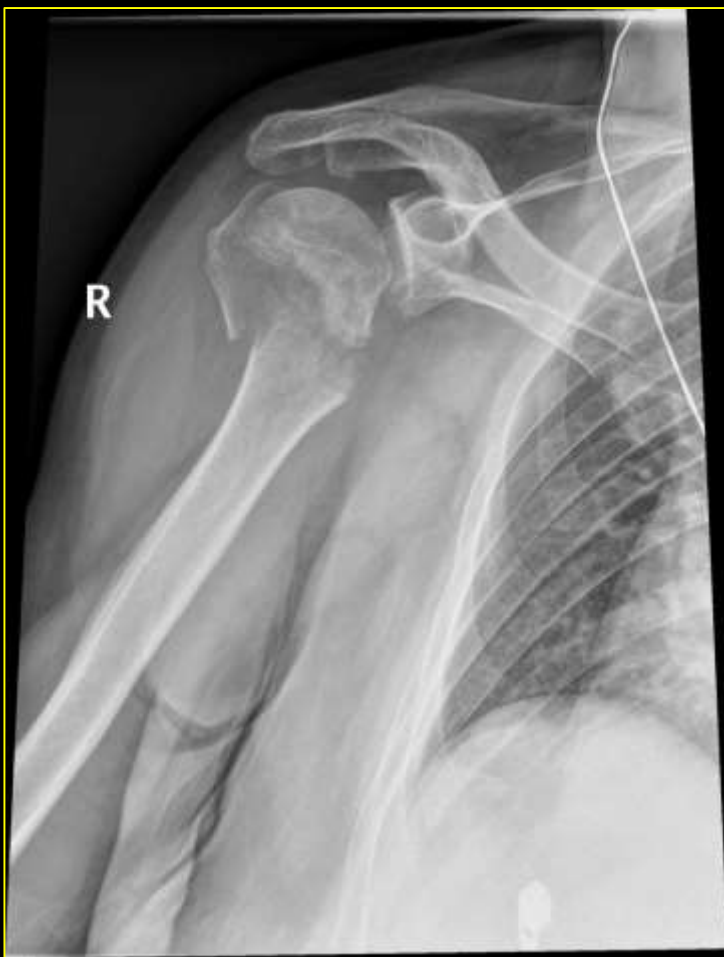# 6 months post surgery



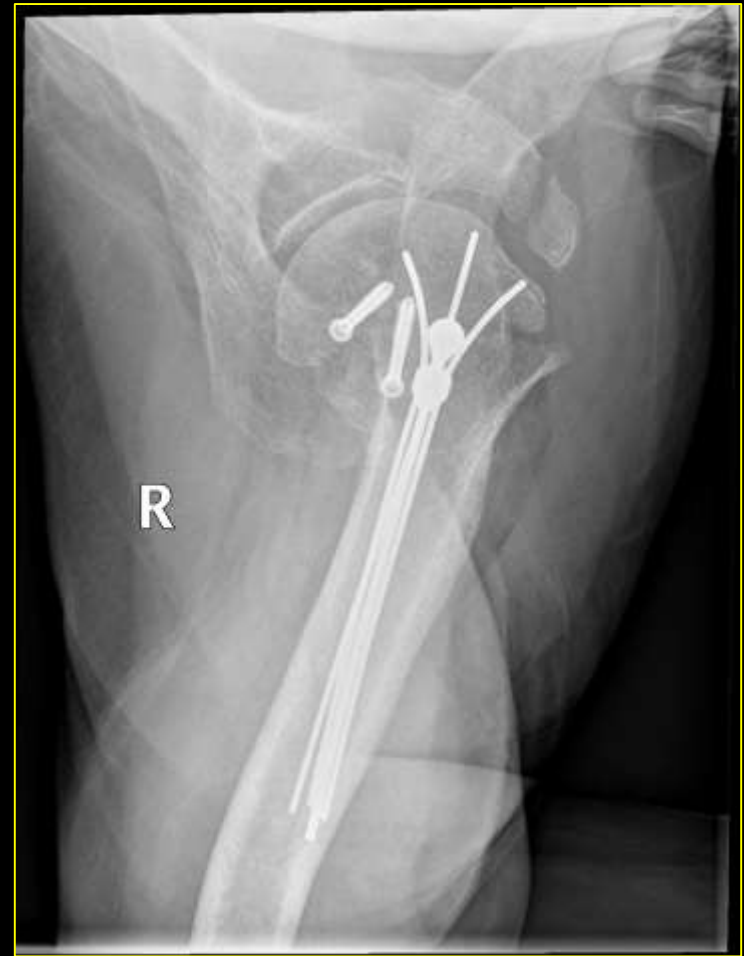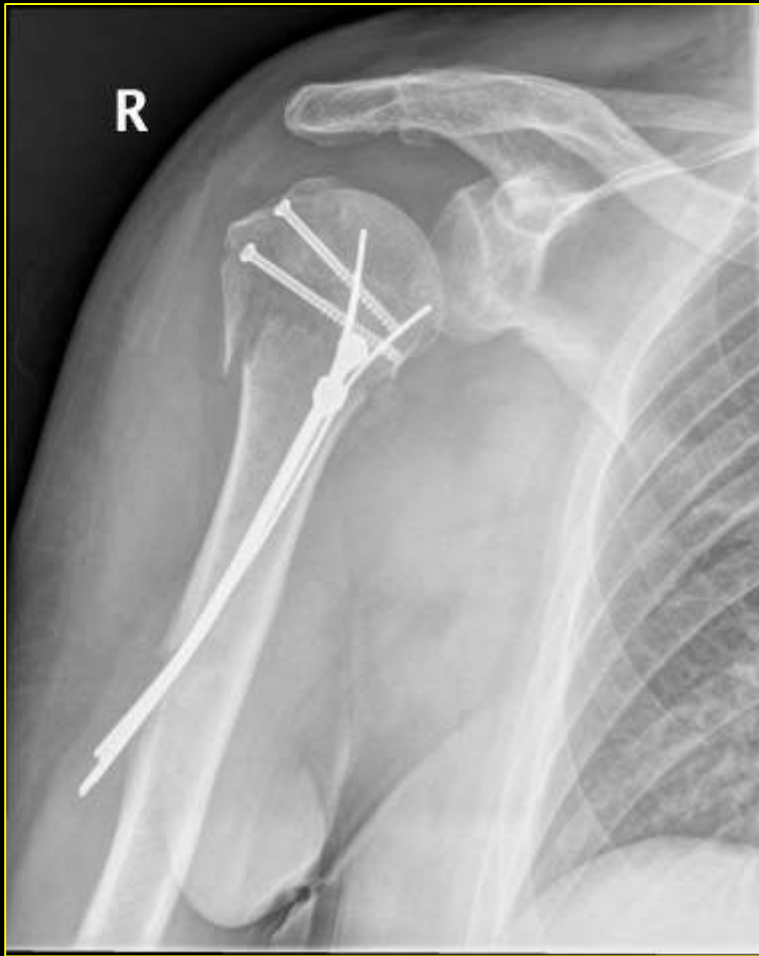# result



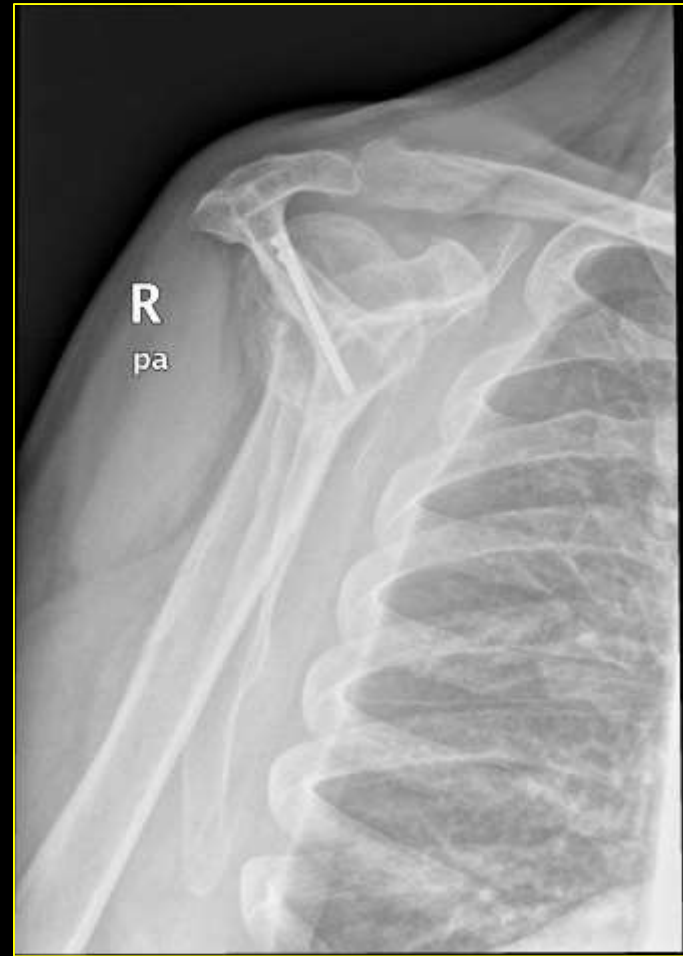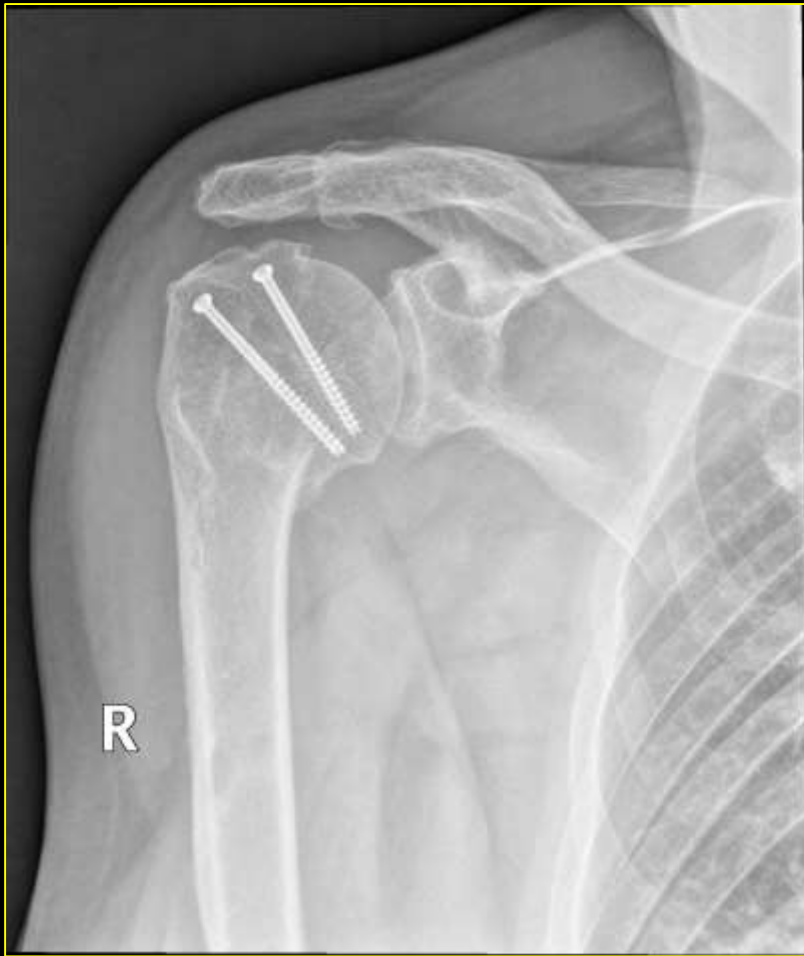# Case 5: 64 male



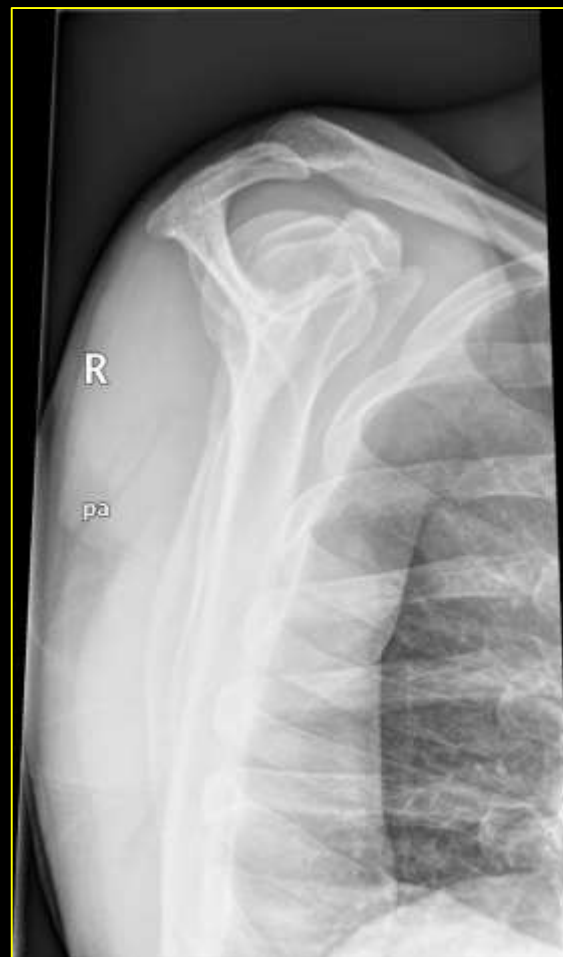
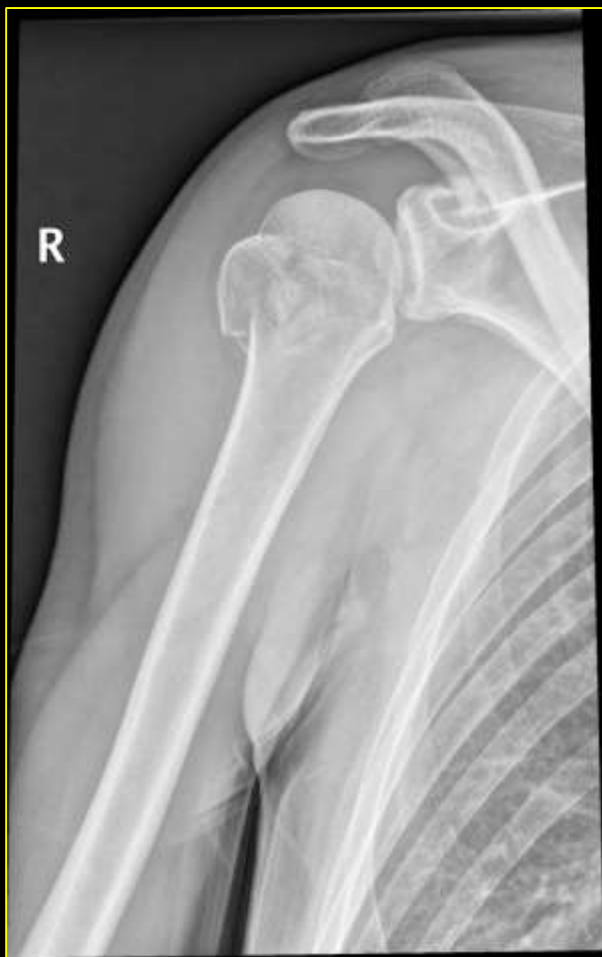# post surgery



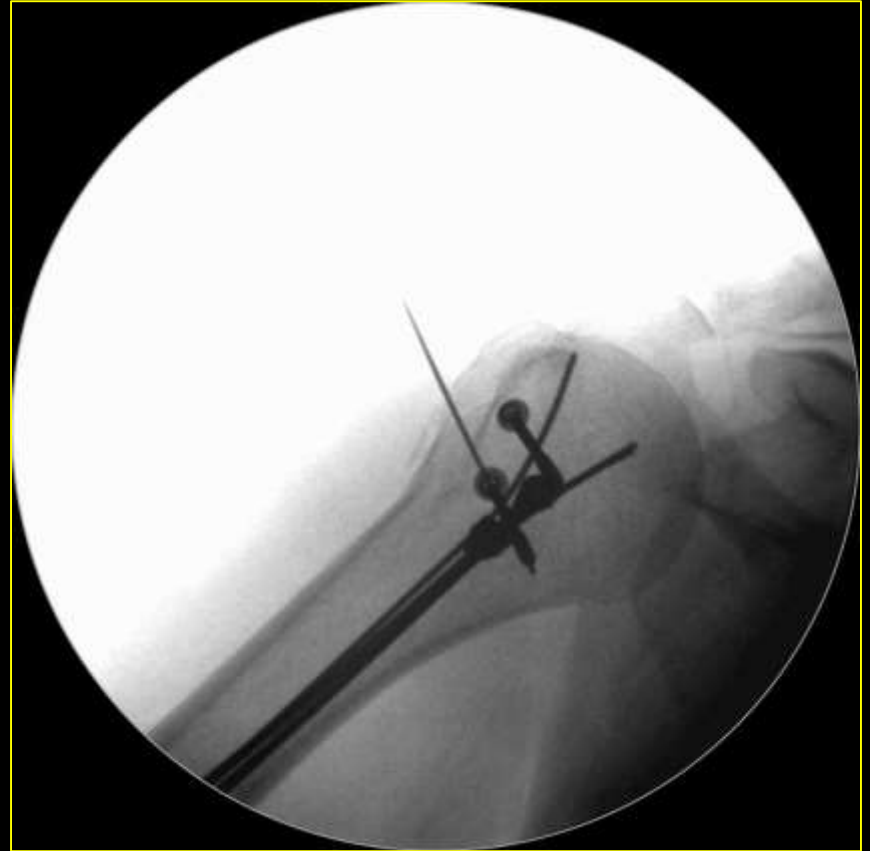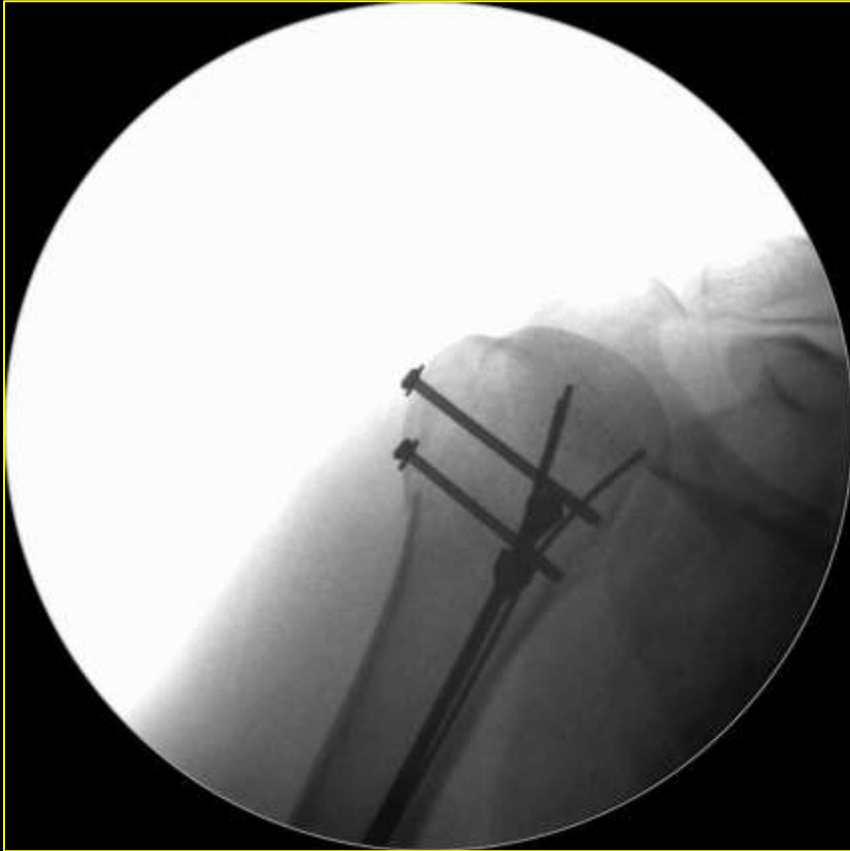# result



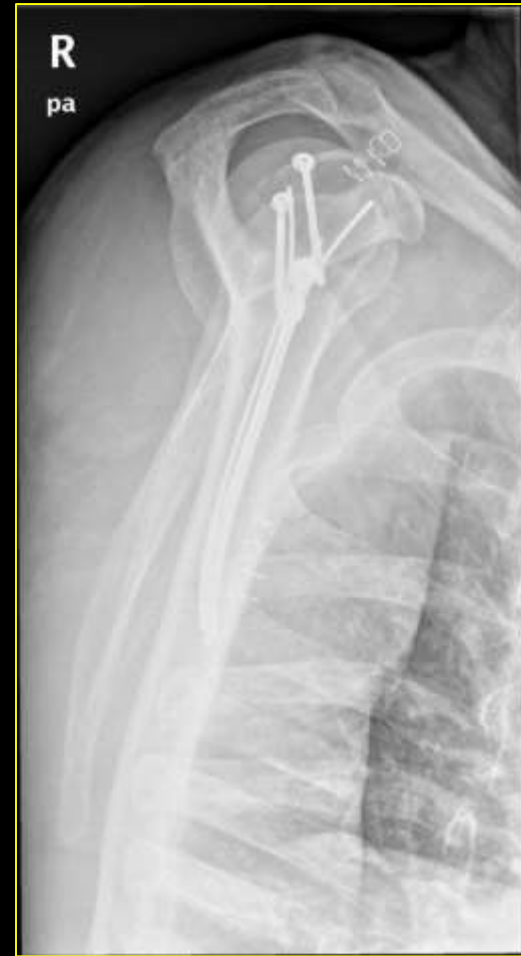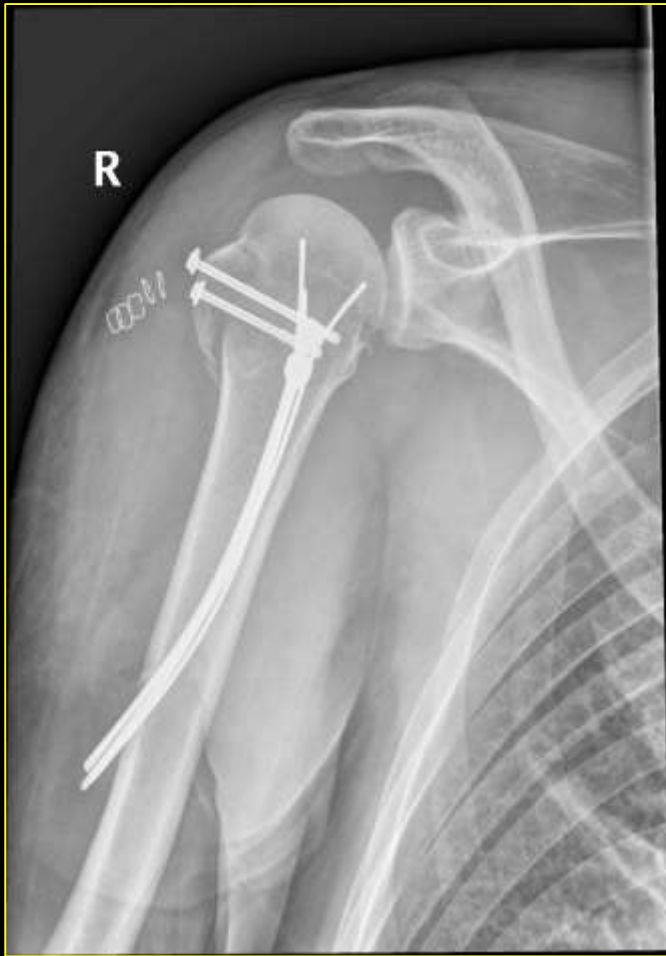# Case 6: 64 male



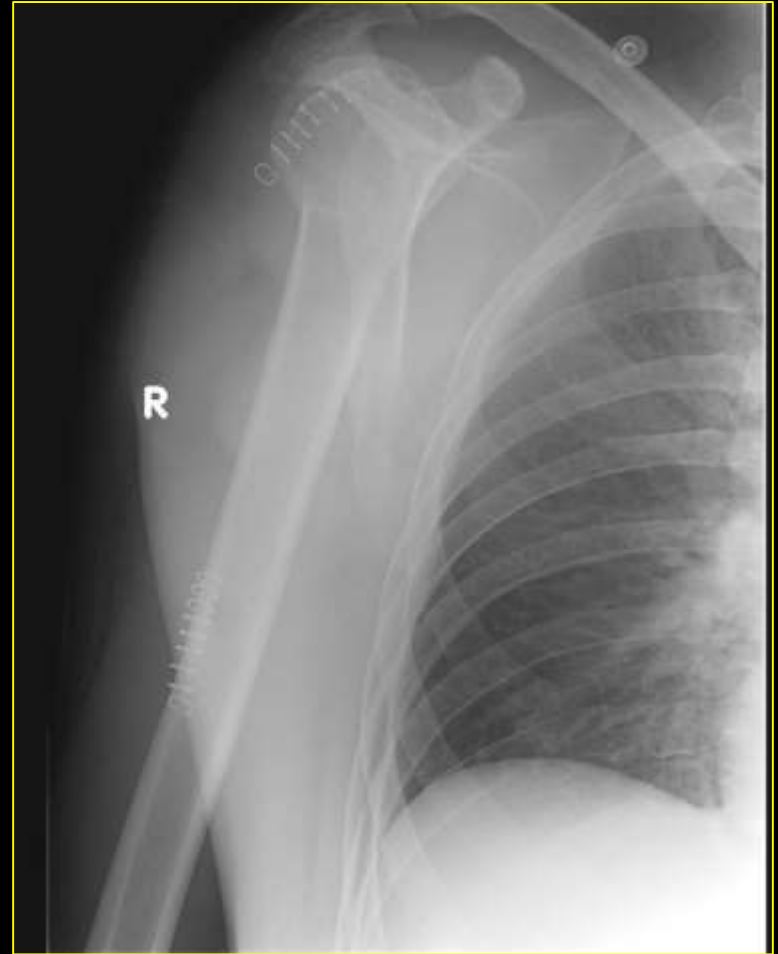
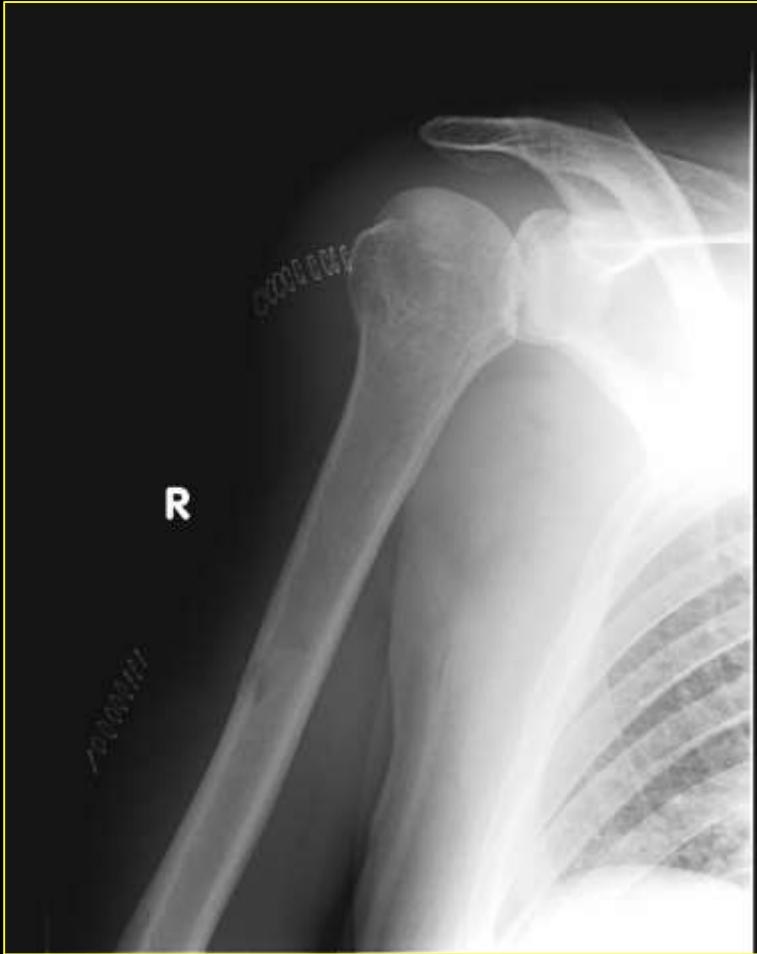# surgery images



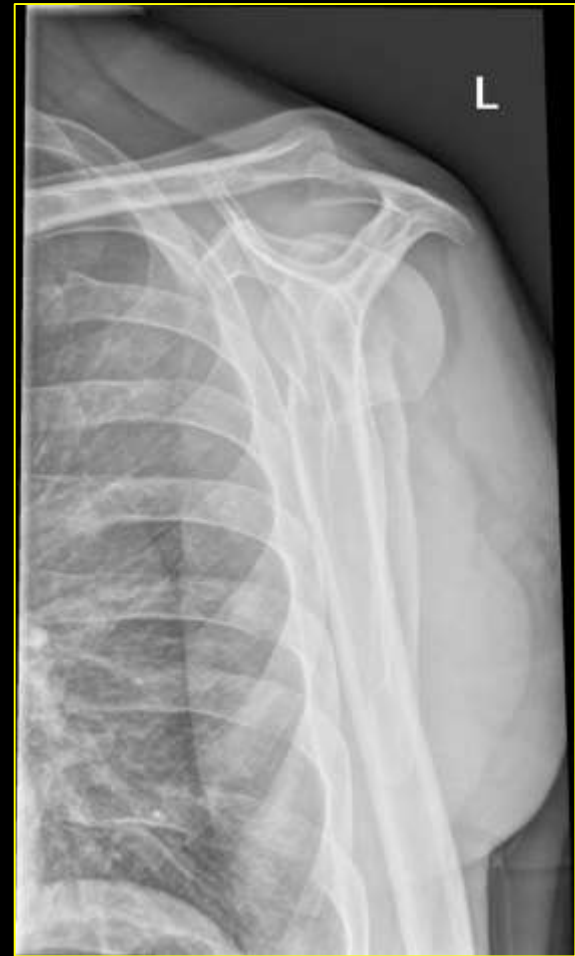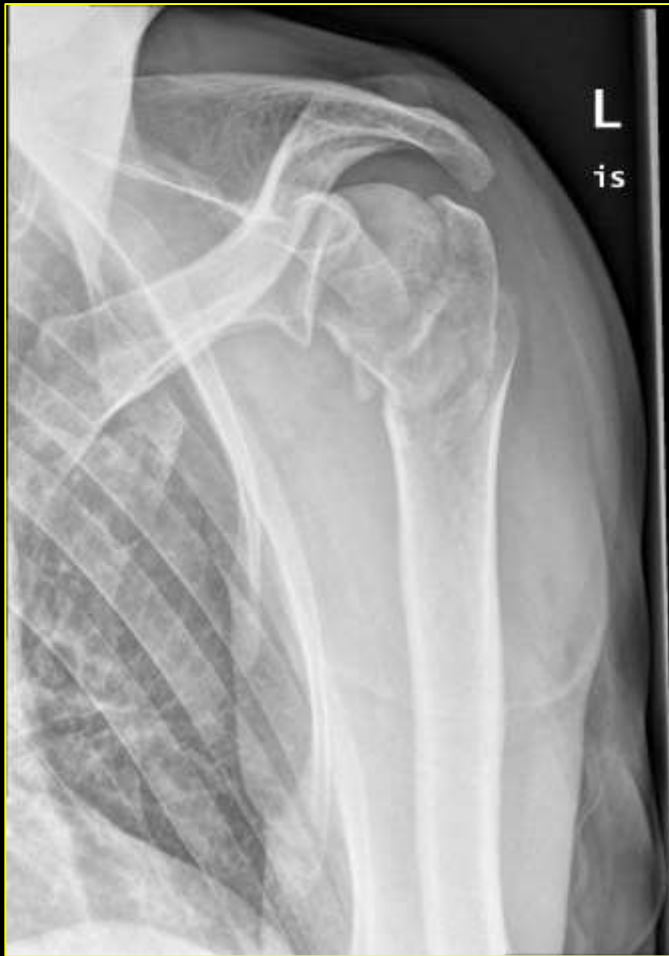# post surgery



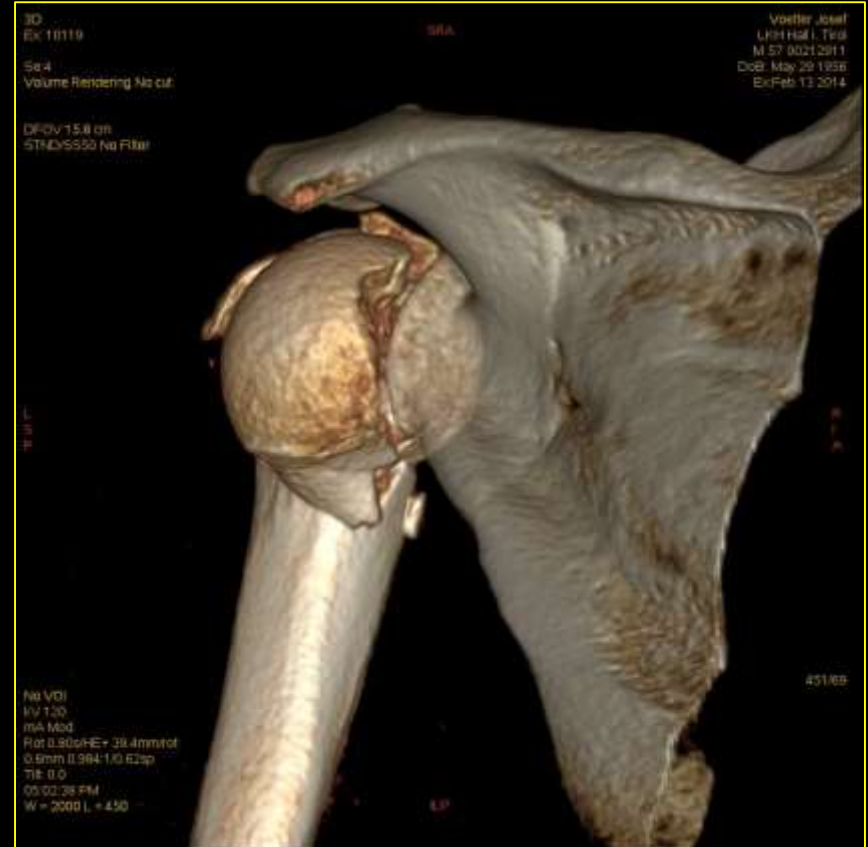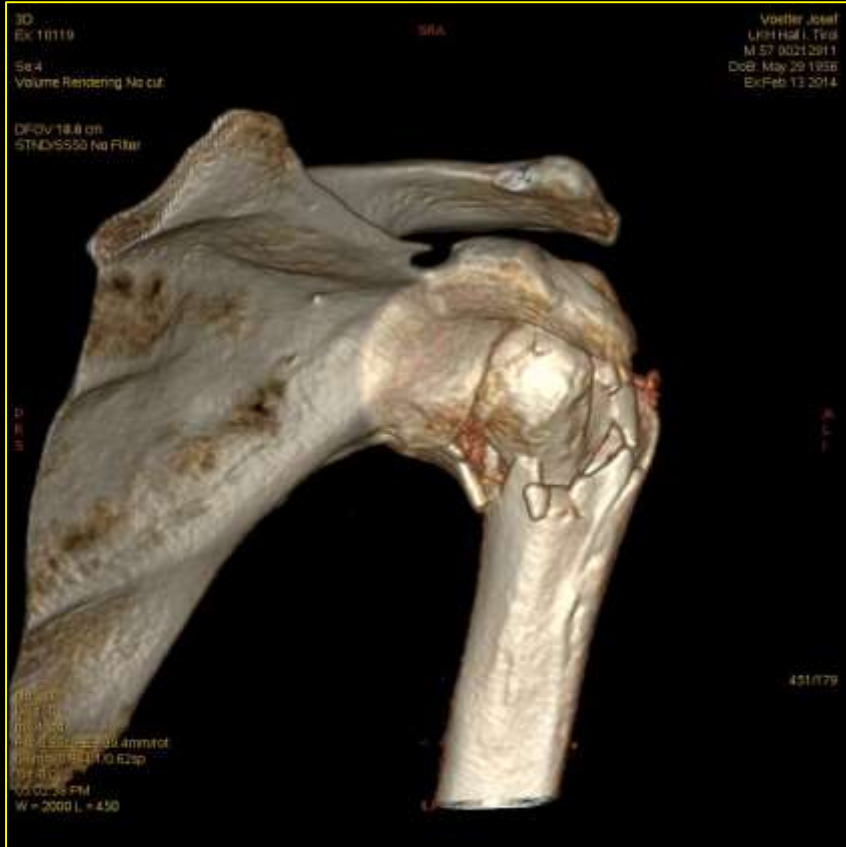# result



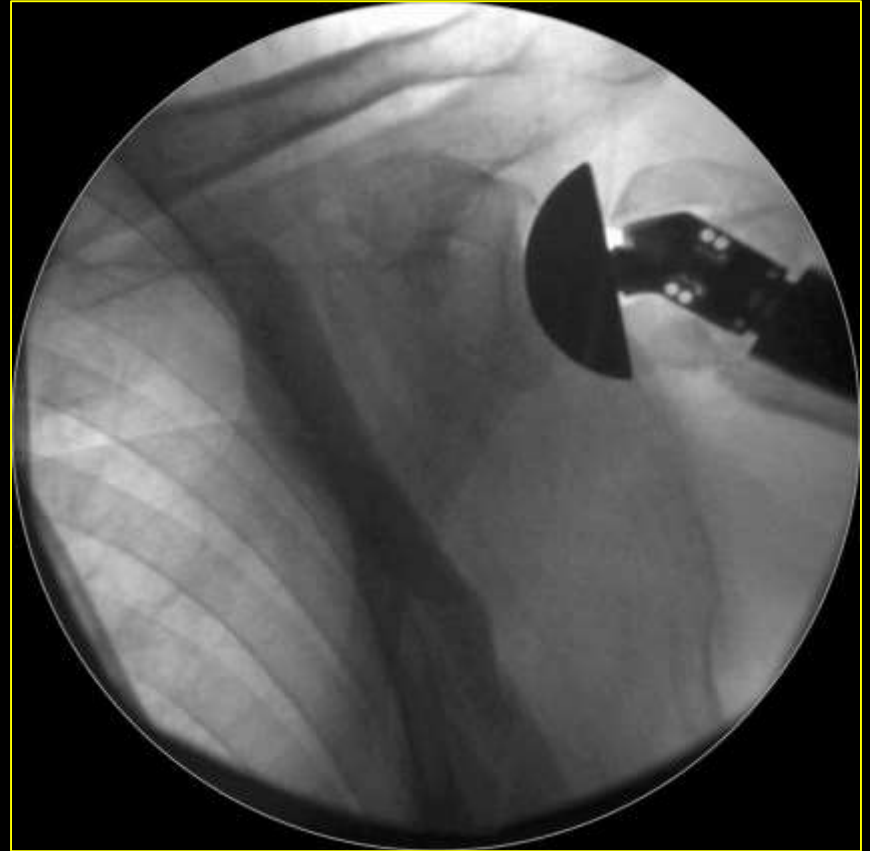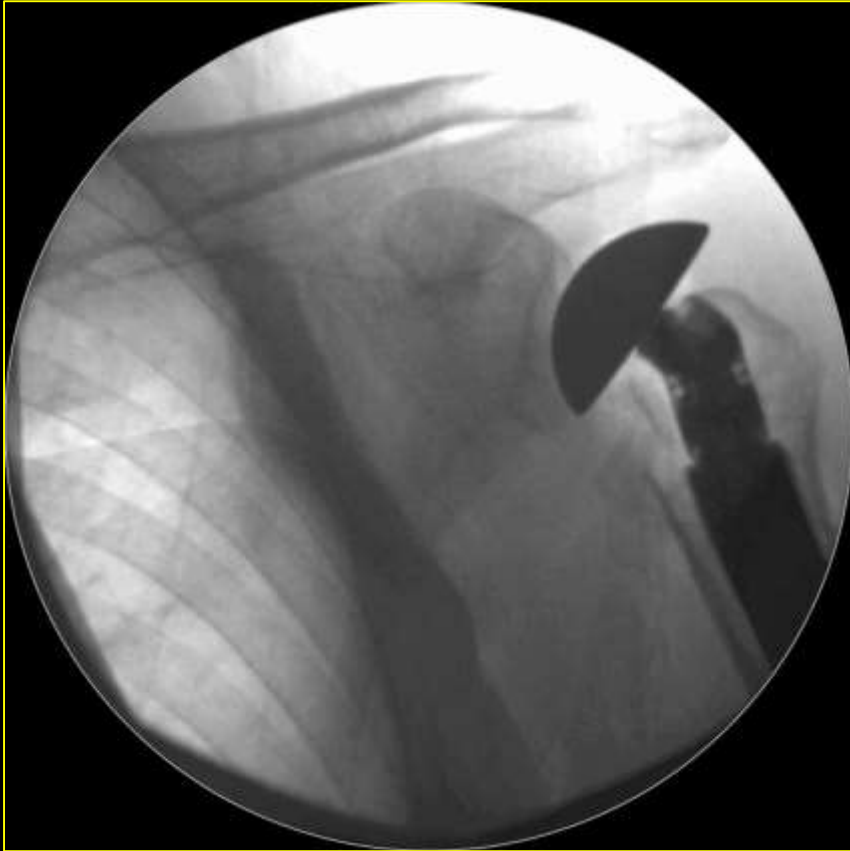# Case 7: 58 male



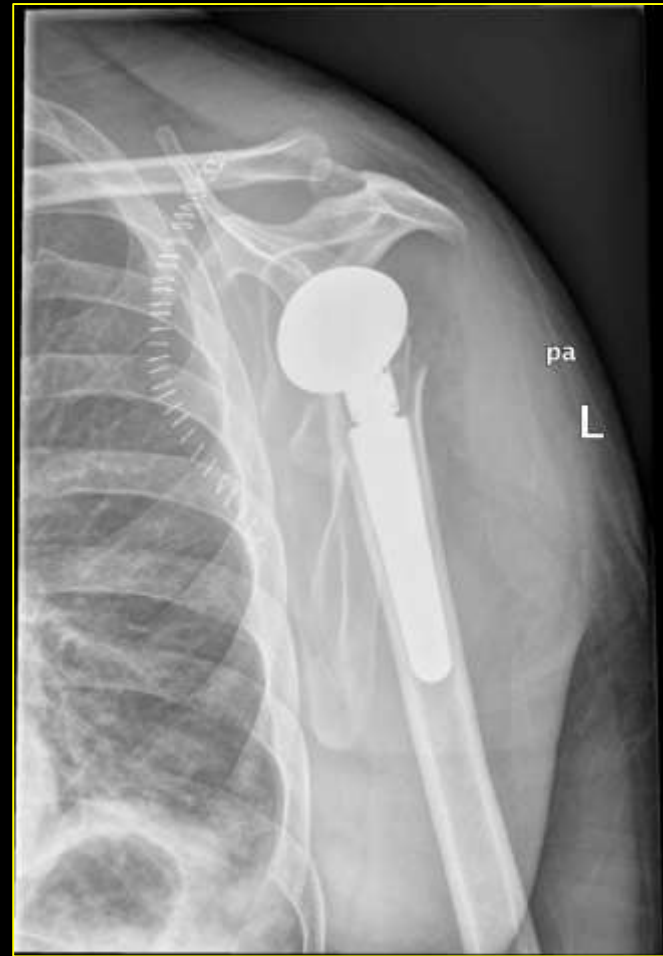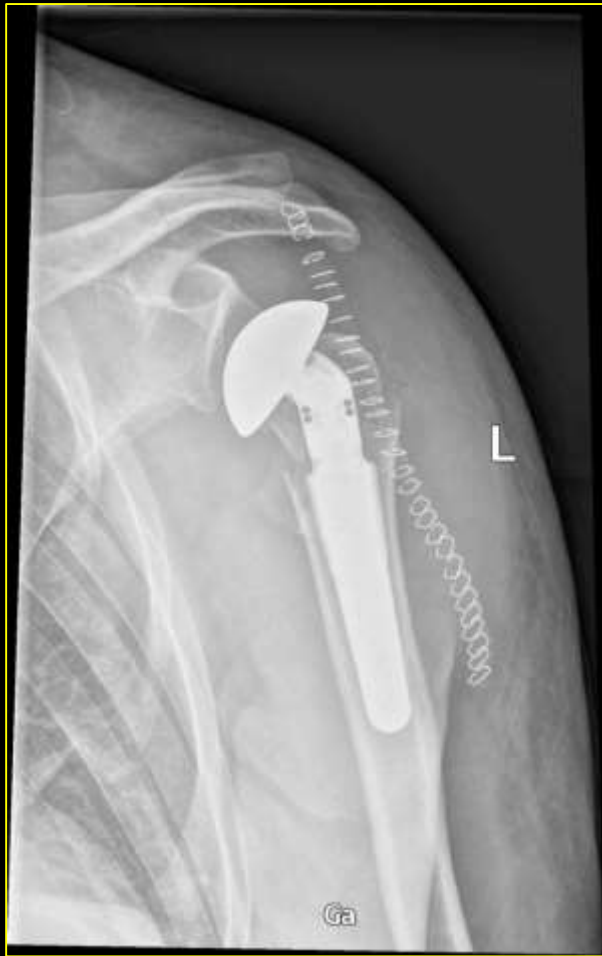# CT images



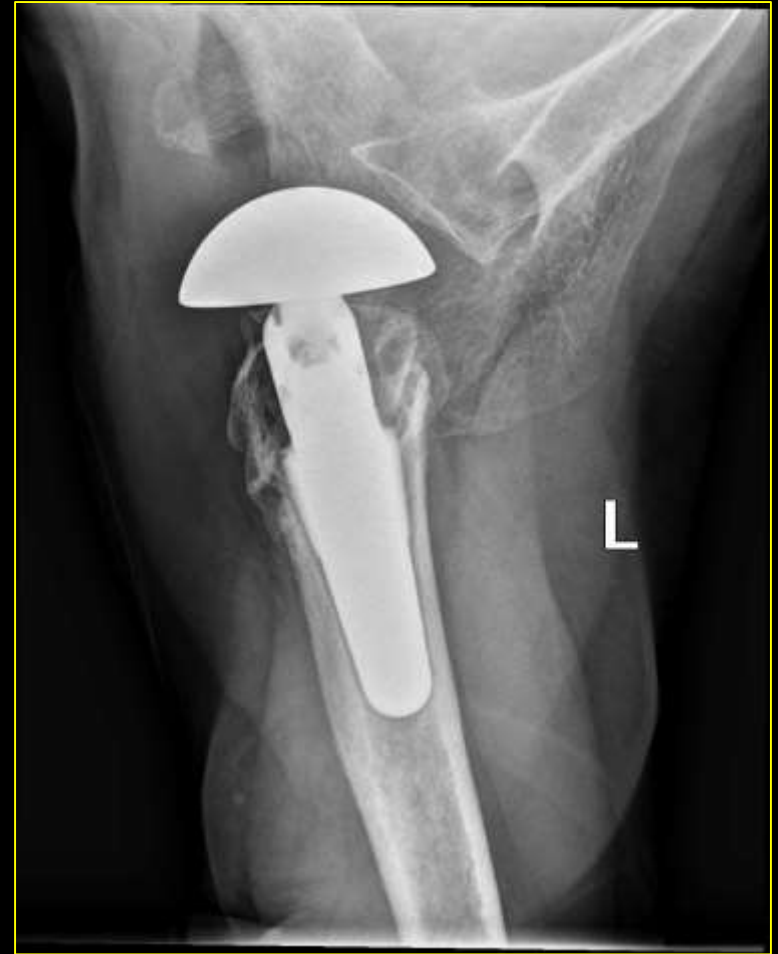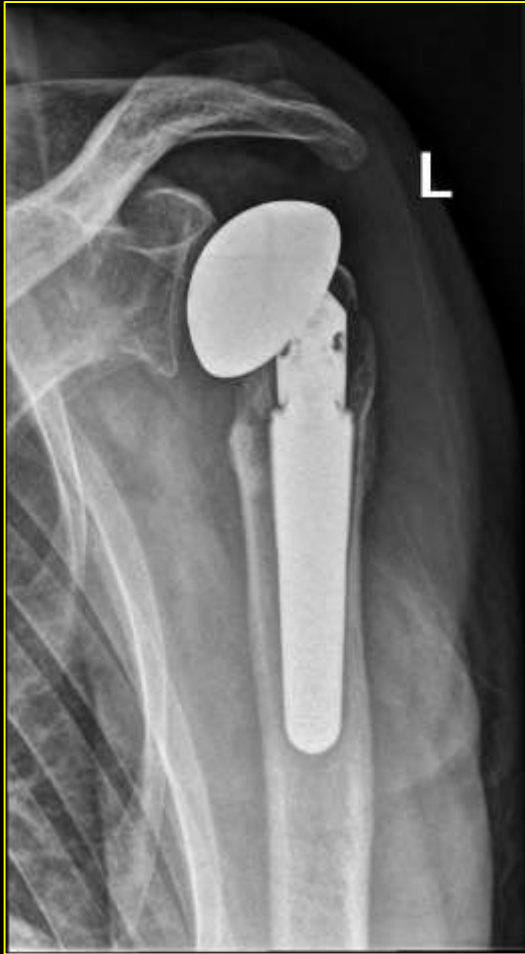# surgery images



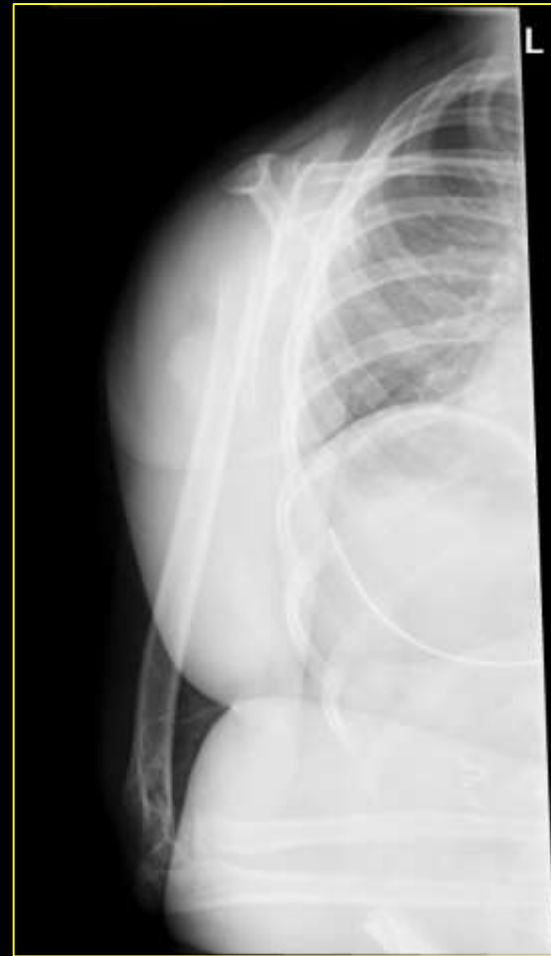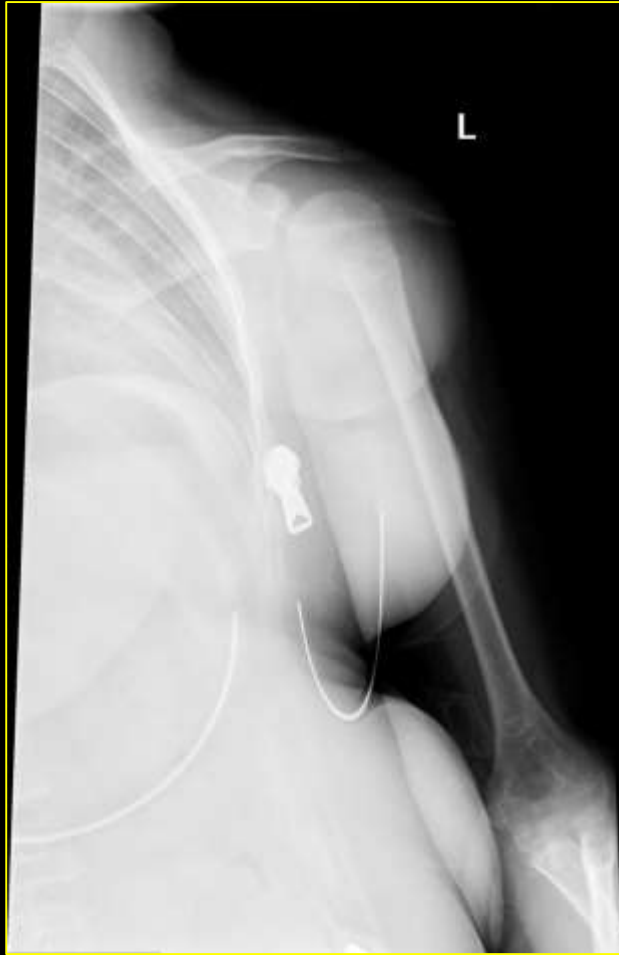# post surgery



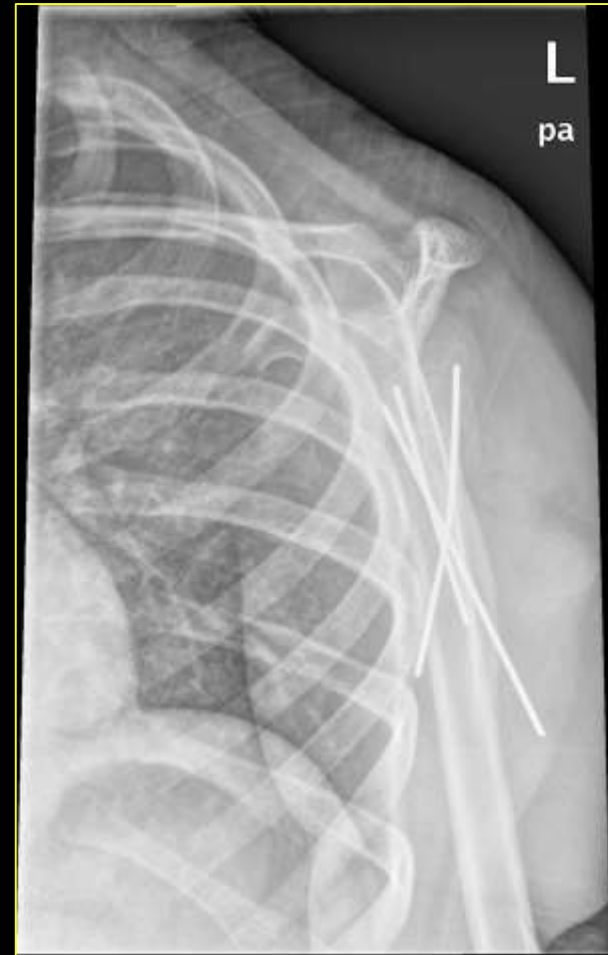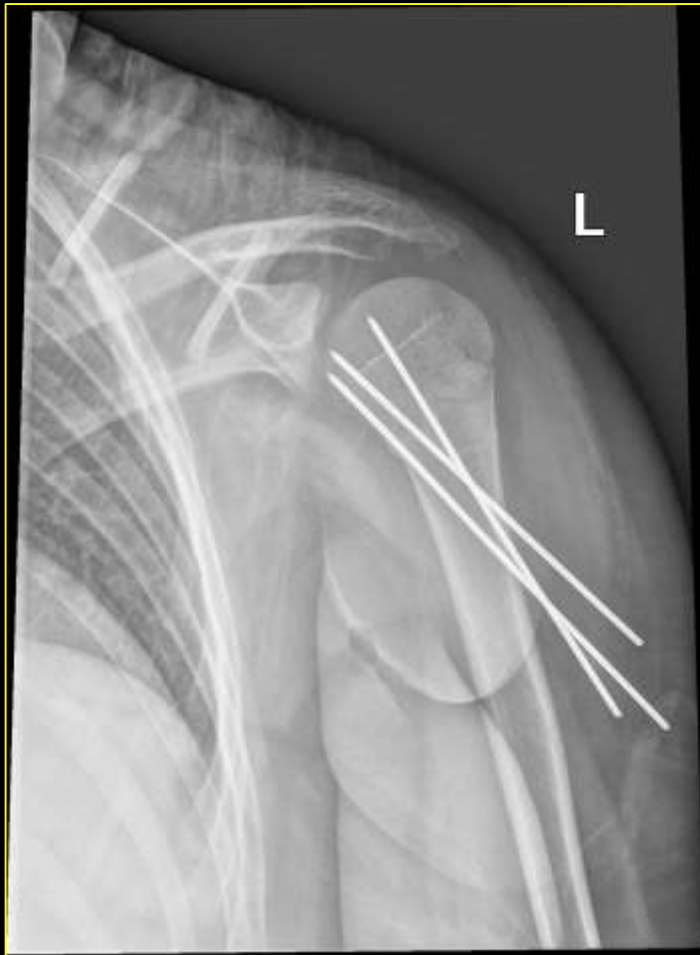
# result



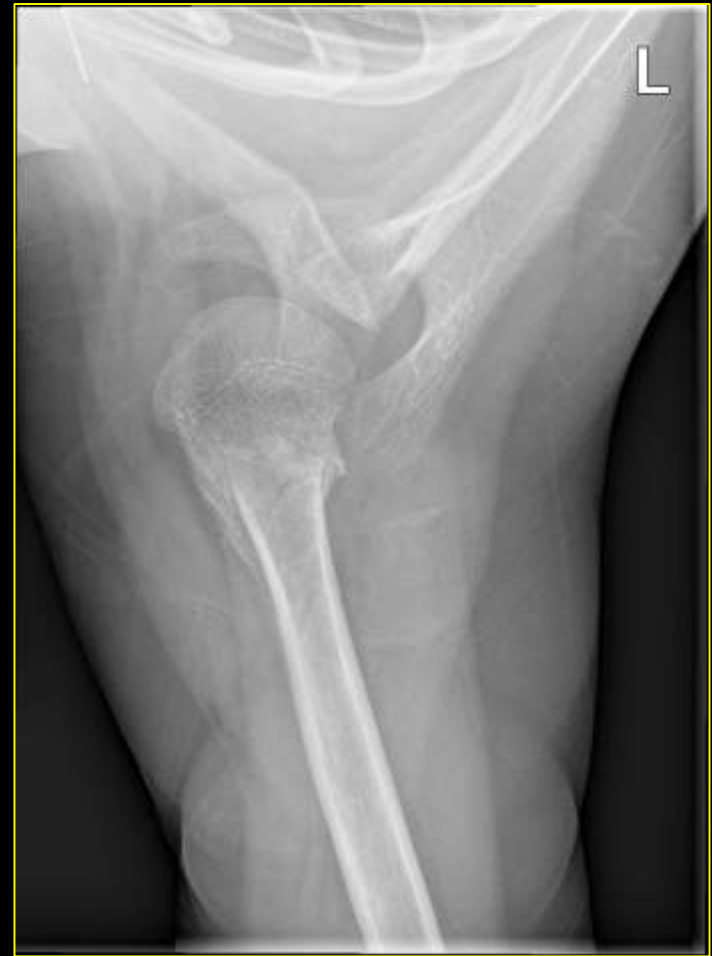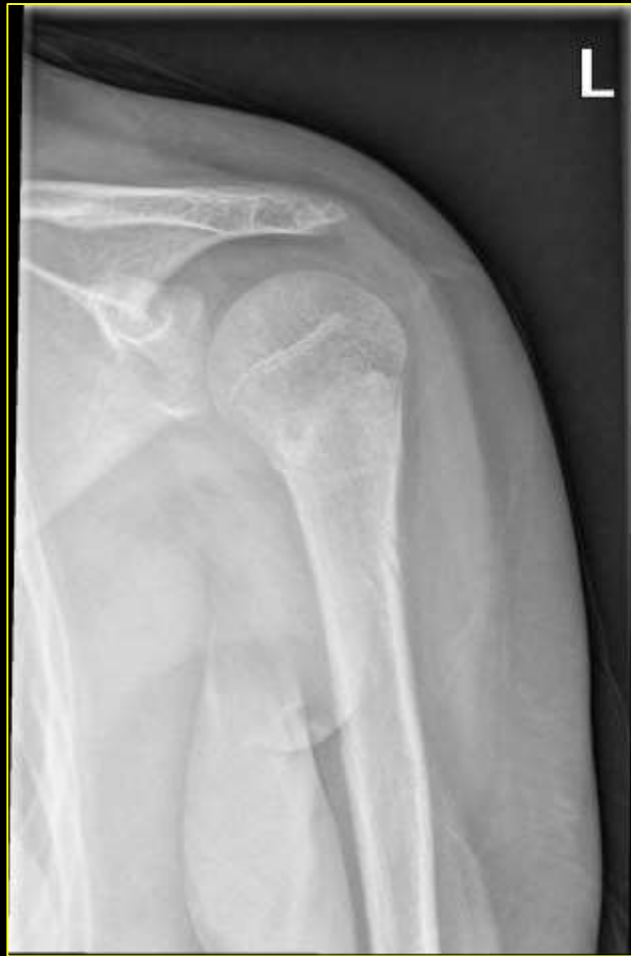# Case 8: 11 female



# post surgery



# result



conclusion

sometimes less can be more